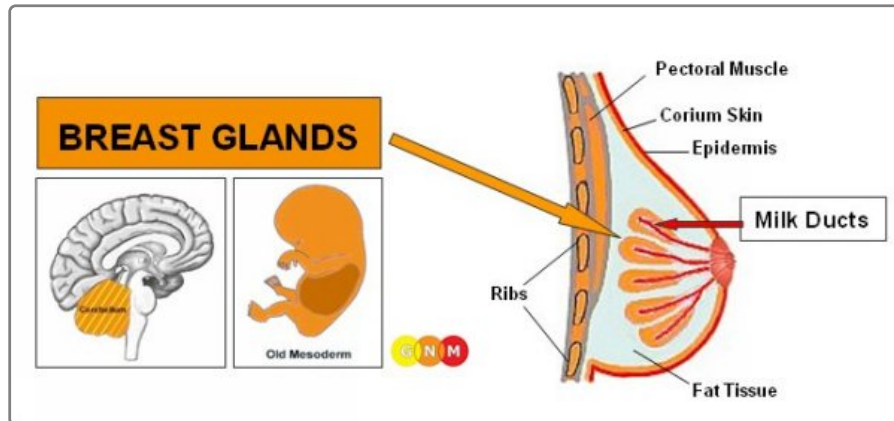


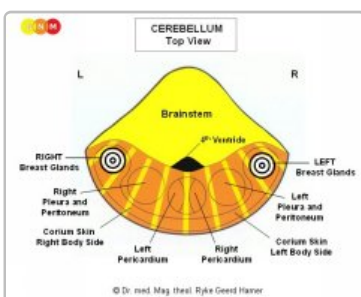
FEMALE BREAST



Biological Conflict Conflict-Active Phase Healing Phase

DEVELOPMENT AND FUNCTION OF THE BREAST GLANDS: Anatomically, the breasts cover the chest (pectoral) muscles in front of the ribs and the sternum. Fat tissue, connective tissue, and ligaments (Cooper's ligaments) provide support to the breasts and give them their shape. The female breasts are mammary glands that contain in each breast 15-20 lobes comprised of many small lobules. The function of the breast glands is to produce milk to feed young offspring. During pregnancy hormones such as prolactin change the glandular tissue in preparation for lactation. When a woman breastfeeds her baby, the milk travels through a network of milk ducts to the nipple at the tip of the breast. The nipple is bordered by a dark area of skin, called the areola. In evolutionary terms, the breast glands developed from sweat glands of the a corium skin. The nipple is an evagination of the corium skin; this is why both the nipples and the areola are highly pigmented. Like the corium skin, the breast glands originate from the old mesoderm and are therefore controlled from the cerebellum.

NOTE: With the rise of mammals, milk lines developed on the right and left side of the midline, reaching from the thorax to the groin area. Normally, human females have two mammary glands, one on either side of the sternum, but breast tissue and nipples may form anywhere along the embryonic milk lines.



BRAIN LEVEL: In the cerebellum, the breast glands in the right breast are controlled from the left side of the brain; the breast glands of the left breast are controlled from the right brain hemisphere (lateral). Hence, there is a cross-over correlation from the brain to the organ.

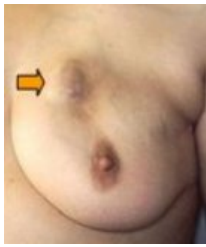NOTE: The right and left milk line are controlled from the same brain relays as the a corium skin.

BIOLOGICAL CONFLICT: In biological terms, the female breast is synonymous for caring and nurturing. The conflict linked to the breast glands is therefore a **nest-worry conflict** concerning the well-being of a loved one (including a pet) or worries about the "nest" itself (distress regarding a woman's home or workplace). The breast glands also correspond to an **argument conflict**. Typically, the argument (with a partner, one of the children, a parent, a friend) has a "worry"-aspect.

CONFLICT-ACTIVE PHASE: Starting with the DHS, during the conflict-active phase breast gland cells proliferate proportionally to the intensity of the conflict. The **biological purpose of the cell increase** is to enhance the function of the breast glands in order to have more milk available when a nest-member is in need (female mammals also nurse the adult males in the event of an emergency). Even if a woman is not breastfeeding at the time or is no longer of childbearing age, her breasts still respond to a worry conflict in this biologically meaningful manner.

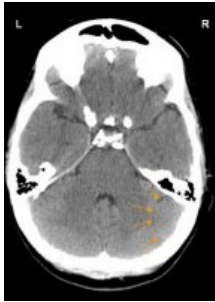NOTE: Whether the right or left breast (or both) is affected is determined by a woman's handedness and whether the conflict is mother/child or partner-related. If the conflict is about the nest itself, it involves the mother/child-breast (left breast for right-handed females, right breast for left-handed females).

With prolonged conflict activity (**hanging conflict**) a compact nodule develops in the breast (it can also form along the **mammary line**). Throughout this period, the nursing mother has more milk in the conflict-related breast. In conventional medicine, the growth is called a **glandular (lobular) breast cancer** or a **mamma carcinoma** (compare with "breast cancer" related to the **milk ducts**); if the rate of cell division exceeds a certain limit, then the cancer is considered "malignant".



This image shows the nodule of a glandular breast cancer in the left breast, caused by a **nest-worry-conflict** concerning her **mother or child** if the woman is **right-handed**. The size of the nodule is determined by the duration and intensity of the conflict.

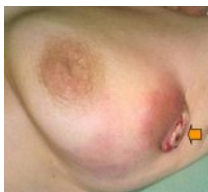Dr. Hamer: "A woman associates the bond with her children and her partner predominantly with her breast. This is why diseases of the breast are the most common medical conditions in women".



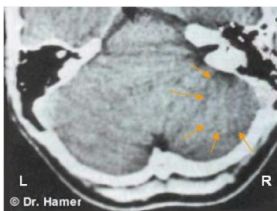
On this brain CT we see the impact of a **nest-worry-conflict** on the right side of the cerebellum (**view the GNM diagram**). It is the brain relay from where a glandular breast cancer in the left breast is controlled. The **sharp border** of the **Hamer Focus** indicates conflict activity.

Breast cancer in men: Men also have **mammary glands**, but the breasts remain undeveloped because of their higher testosterone level (in females, estrogen promotes the development of the breasts). However, if a man has a low testosterone level due to an active **loss conflict** (see **testicles**) or a **conflict-related hormonal imbalance**, he can suffer a **nest-worry-conflict** just like a woman. Men usually don't pay attention to breast nodules, neither do they (have to) go for mammograms, which is why the number of breast cancers found in men is very low. **NOTE:** Male lactation occurs with a conflict related to the **pituitary gland** that secretes prolactin, the hormone that stimulates the breast glands to produce milk.

HEALING PHASE: Following the **conflict resolution (CL)**, the cells that are no longer needed are broken down with the help of **fungi, TB bacteria** or other **bacteria**. During this process an **abscess** forms in the breast. **Healing symptoms** are **swelling** due to the **edema** (fluid accumulation) in the healing breast (in **PCL-A**) and **night sweats**. With the **SYNDROME**, that is, with **water retention** as a result of an active **abandonment and existence conflict**, the swelling becomes much larger. The repair of the breast tissue is noticeable as **sharp pain**, which is characteristic for the healing of all **old-mesodermal tissues** (see **shingles**). The extent of the symptoms is determined by the degree and duration of the **conflict-active phase**. Depending on the size of the tumor, the healing process can take several months.



When the pressure of a tumor breaks the overlying **epidermis**, the bloody and **foul-smelling discharge** finds its way through the external opening to the outside of the breast (left breast in this picture).



On a brain scan, the healing phase (**PCL-A**) of a glandular breast cancer in the left breast presents as "swollen", edematous rings (**brain edema**) in the breast gland relay located on the right side of the cerebellum (**view the GNM diagram**).

Complications with glandular breast cancer arise when the **corium skin** of the affected breast undergoes a healing phase at the same time (see **skin tuberculosis**). This happens either with an "attack conflict" triggered, for example, by a **breast biopsy** or when a woman suffers a "disfigurement conflict" evoked by the appearance of her breast. With a **hanging healing** the breast oozes constantly (watch the **protein loss!**) contributing, additionally, to "feeling soiled"-conflicts. In this case, surgery might have to be considered.

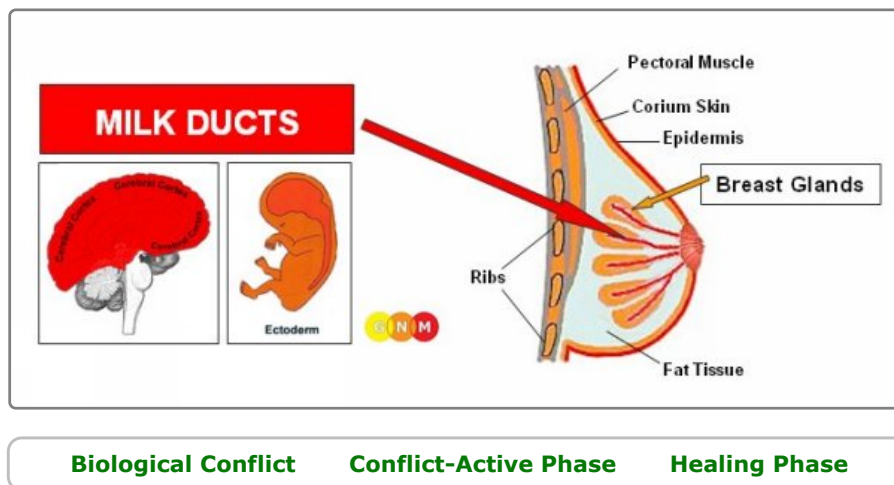
The by-products of the cell removal process are eliminated through the **lymphatic system**. The lymph fluid travels predominantly to the axillary lymph node located in the armpit of the healing breast. Hence, in the healing phase the lymph node swells up.

Women who have breast cancer often suffer a **self-devaluation conflict** leading to the development of a **lymphoma** in

the axillary node. In conventional medicine, the new "tumor" is interpreted as a "metastasizing cancer", based on the wrong assumption that the lymph vessels are pathways for "spreading cancer cells". If the self-devaluation conflict is more severe, usually following a **mastectomy**, this affects the **sternum or ribs** underneath the amputated breast (see **bone cancer**). The mastectomy could also trigger an "attack conflict" with the development of a **melanoma** in the area of the surgical scar. Potential complications occur when the fluid from the edema enters the pleura causing a **transudative pleural effusion**. The self-devaluation conflict ("my breast looks ugly") could also involve the **fat tissue** with a localized swelling (see **lipoma**) in the breast during the healing phase. It is not uncommon that such a growth is misdiagnosed as a breast cancer, or "metastasis".

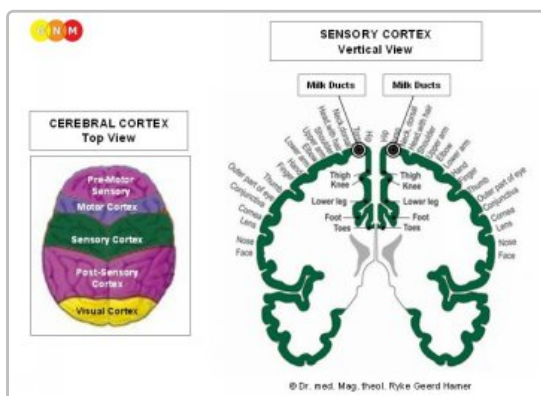
After the tumor has been decomposed by bacteria, a **cavern** remains at the site (see also **lung caverns**, **liver caverns**, **pancreas caverns**) that is eventually filled with calcium. On a mammogram the calcium deposits show as **macrocalcification** (compare with **microcalcification** in the **milk ducts**). Concurrent **water retention** due to the **SYNDROME** inflates the cavern creating a **breast cyst** (compare with **breast cysts in the milk ducts**). So-called **fibrocystic breasts** are the result of recurring healing and scarification processes (PCL-B) in the breast.

If the required microbes are not available upon the resolution of the conflict, because they were destroyed through an overuse of **antibiotics**, the additional cells remain. Eventually, the tumor becomes encapsulated with connective tissue. Such an encapsulated nodule might be found years later during a mammogram, often with dire consequences.



DEVELOPMENT AND FUNCTION OF THE MILK DUCTS: The milk ducts are a structured network of ducts that attach to the lobules of the **breast glands**. They merge into the main mammary ducts at the nipple. The nipples are small projections of the **skin** endowed with special nerves making them sensitive to stimuli such as touch. In lactating females, the milk ducts carry milk to nurse the infant. The inner lining of the milk ducts consists of **squamous epithelium**, originates from the **ectoderm** and is therefore controlled from the cerebral cortex.

NOTE: Once the **breast glands** developed, squamous epithelial cells migrated from the **outer skin** through the nipples into the milk ducts.

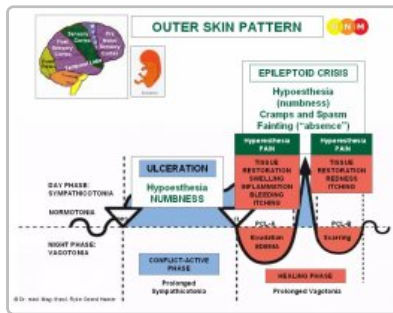


BRAIN LEVEL: The epithelial lining of the milk ducts is controlled from the **sensory cortex** (part of the cerebral cortex). The milk ducts in the right breast are controlled from the left side of the cortex; the milk ducts in the left breast are controlled from the right cortical hemisphere. Hence, there is a cross-over correlation from the brain to the organ.

BIOLOGICAL CONFLICT: The **biological conflict** linked to the milk ducts is a **separation conflict** experienced as if a loved one was „torn from my breast“ (compare with **loss conflict** related to the **ovaries**). Women suffer separation conflicts through an unexpected divorce, a break-up with a partner, her child, a parent, or a friend or when a beloved person (or pet) dies. The fear of a separation can already activate the conflict. Similarly, the milk ducts correlate to the distress of **wanting to separate**, let's say, from a spouse or from a parent because of a betrayal, constant fighting, or abuse. The separation from a home (a woman's "nest") also corresponds to the milk ducts (compare with **nest-worry-conflict** linked to the **breast glands**). The loss of the "nest" is the equivalent to the male **territorial loss conflict**.

In line with evolutionary reasoning, **territorial conflicts**, **sexual conflicts**, and **separation conflicts**

are the primary conflict themes associated with organs of **ectodermal** origin, controlled from the sensory, pre-motor sensory and post-sensory cortex.



The **Biological Special Program** of the milk ducts follows the **OUTER SKIN PATTERN** with hyposensitivity during the conflict-active phase and the Epileptoid Crisis and hypersensitivity in the healing phase.

CONFLICT-ACTIVE PHASE: ulceration in the lining of the milk ducts proportional to the degree and duration of conflict activity. The ulceration occurs in the branches exiting the lobules of the **breast glands** or in the **main ducts close to the nipple**. A severe **separation conflict** could affect all milk ducts in the conflict-related breast. The **biological purpose of the cell loss** is to widen the ducts so that the milk that is no longer required (due to the separation) can drain off easier; the larger lumen of the ducts prevents a congestion of milk in the breast. The ulceration usually goes unnoticed because of the hyposensitivity in the milk ducts during the conflict-active phase (Outer Skin Pattern). The **loss of sensitivity** might reach into the **nipple**.

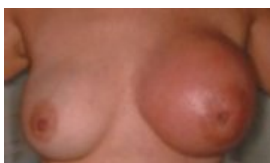NOTE: Whether the right or left breast is affected is determined by a woman's **handedness** and whether the conflict is **mother/child** or **partner**-related. If the conflict is about the nest itself, it involves the mother/child-breast, i.e., the left breast for a **right-handed** female, the right breast for the **left-handed** female.

With persistent conflict activity the continuous ulceration contracts the milk ducts resulting in **cirrhous knots** and painful pulling in the breast. The contraction is visible as a local retraction at the breast and an **inverted nipple**. The affected breast becomes considerably smaller (recurring scarification because of a **hanging healing** in PCL-B also makes the breast smaller). On a mammogram a cirrhous knot might appear in the shape of a compact nodule and subsequently diagnosed as a cancer ("**cirrhous carcinoma**"), even though there is no "cancer cell" mitosis!

The conflict-active phase is accompanied by a **short-term memory loss** that reaches into PCL-A. This is characteristic for all **separation conflicts** (see **Biological Special Program** related to the **skin**).

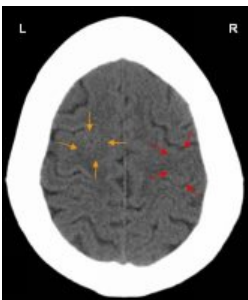
HEALING PHASE: During the first part of the **healing phase** (PCL-A) the tissue loss is replenished through **cell proliferation**. The **breast is swollen, red, hot, and itchy**. When the separation is also associated with the **skin**, a **rash** develops on the breast as well (see **Paget's disease**). In the healing phase the sensitivity returns, markedly with **hyperesthesia**, a heightened sensitivity to touch, specifically at the nipple. The swelling makes the nipple appear inverted (compare with inverted nipple in the conflict-active phase).

In conventional medicine, the cell proliferation in the milk ducts is diagnosed as an **intraductal breast cancer**, with an inflammation as an **inflammatory breast cancer** (compare with **breast cancer** related to the **breast glands**). Based on the **Five Biological Laws**, the new cells cannot be regarded as "cancer cells" since the cell increase is in reality a replenishing process.



This picture presents the healing phase of an intraductal breast cancer in the left breast.

The theory that breast cancer is linked to "**abnormal genes**" cannot explain why the "tumor" develops in the right or left breast, why it affects the milk-ducts or the **breast glands**, or why the "cancer" occurs at a certain time in a woman's life.



The red arrows on this CT scan point to the area of the brain (in the sensory cortex) from where the healing of an intraductal breast cancer in the left breast (**view the GNM diagram**) is controlled. The uneven, partly **edematous ring** of the **Hamer Focus** confirms that the woman (she is **left-handed**) has resolved a **separation conflict** related to her **partner**.

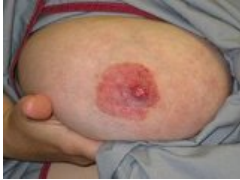However, she is still conflict active with an **overwhelmed-conflict** associated with her **child**, involving the left **myocardium**. The **Hamer Focus** shows as a **sharp ring configuration** in the corresponding brain relay in the motor cortex (orange arrows). The two conflicts occurred most likely together.

With the **SYNDROME** due to an active **abandonment and existence conflict** the **retained water** is exceedingly stored in the healing breast, which increases the swelling. A large swelling might **occlude the milk ducts**. In this case, the discharge produced during the repair process becomes clogged in the breast, particularly behind the nipple. Biologically, this complication is not planned because if a female is nursing, the baby would normally suck the breast dry (adult mammals suck the udder of the female when the milk is congested). In non-lactating women, however, the secretion has no outlet, which increases the swelling and the pain. **Dr. Hamer** therefore recommends to drain the fluid

twice a day with a milk pump or have it sucked out by her partner, a friend, or her midwife since this is less painful (the discharge has a slightly sweet taste like milk). If a **scirrhotic breast** is not drained during the healing phase, the breast becomes small and hard.

A **leaking breast** is an indication that the milk duct is not entirely blocked. The secretion emptying through the nipple is a clear or bloody fluid (compare with **smelly discharge** when a glandular breast tumor is healing and **milky discharge** related to the prolactin-producing **pituitary gland**). With concurrent **water retention**, the swelling in a milk duct is usually diagnosed as a **breast cyst** (compare with **breast cyst in the breast glands**).

Mastitis (periductal mastitis) occurs when the ducts under the nipple become inflamed. Mothers who are separated from their baby, for example after delivery, develop mastitis as soon as they are able to nurse their infant uninterrupted. **Lactation mastitis** or an **inflammation of the nipple (thelitis)** is either linked to a **separation conflict** or, in breast-feeding women, when the nursling is sucking too strong. A wart in the milk duct (**intraductal papilloma**) is the result of recurring and **prolonged healing**.



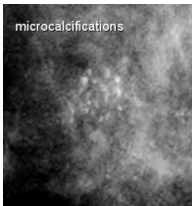
If the healing process involves the nipple, including the areola, this is diagnosed as **Paget's disease**. In conventional medicine, it is considered a breast cancer!

An **eczema** on the areola (see **epidermis**) indicates that the **separation conflict** from a **child or partner** was associated with that particular part of the breast, for example, when breastfeeding is discontinued (hospitalization of the nursling or the mother) or through a loss of physical contact related to that area. Hence, "Paget's disease" and an intraductal breast cancer can easily occur together.

The **Epileptoid Crisis** manifests as acute pain. The pain is not of a sensory nature but a strong pulling pain. Pain also occurs in **PCL-B**; in this case due to the scarification process.

NOTE: All **Epileptoid Crises** that are controlled from the **sensory, post-sensory, or pre-motor sensory cortex** are accompanied by **troubled circulation, dizzy spells**, short **disturbances of consciousness** or a complete **loss of consciousness** (fainting or "absence"), depending on the intensity of the conflict. Another distinctive symptom is a **drop of blood sugar** caused by the excessive use of glucose by the brain cells (compare with **hypoglycemia** related to the **islet cells of the pancreas**).

After the **Epileptoid Crisis**, the swelling of the breast goes down.



On a mammogram, the **completion of the healing process** shows as specks of calcium, or **microcalcifications** (compare with **macrocalcification** in the **breast glands**) caused by the temporary backup of the milky discharge. In today's medicine, however, microcalcifications in the breast are considered an early sign of breast cancer!