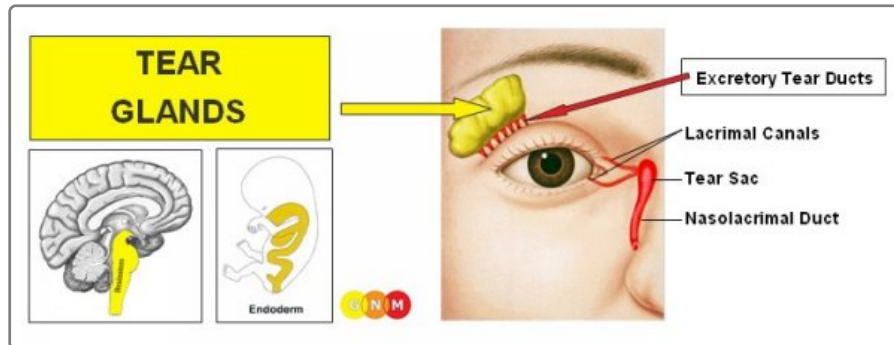
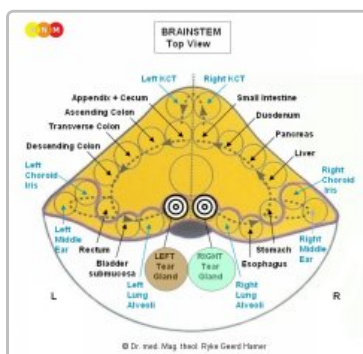


## EYES



Biological Conflict    Conflict-Active Phase    Healing Phase

**DEVELOPMENT AND FUNCTION OF THE TEAR GLANDS:** The tear glands are located in the temporal orbit (eye socket) on the outer portion of the upper eyelids. They produce the watery layer of the tear film that keeps the outer part of the eye and the conjunctiva moist. The tear fluid reaches the eye through the excretory tear ducts. Excess tears drain through the lacrimal canals, tear sac, and nasolacrimal duct into the nasal cavity. In evolutionary terms, the tear glands developed from the intestinal mucosa of the original gullet. Like the intestinal cells that digest the “food morsel”, the biological function of the tear glands is to “digest” (secretory quality) the “visual morsel”. The tear glands consist of intestinal cylinder epithelium, originate from the endoderm and are therefore controlled from the brainstem.



**BRAIN LEVEL:** In the brainstem, the tear glands have two control centers that are orderly positioned within the ring form of the brain relays that control the organs of the alimentary canal.


The right tear gland is controlled from the right side of the brainstem; the left tear gland is controlled from the left brainstem hemisphere. There is no cross-over correlation from the brain to the organ.

**NOTE:** The mouth and pharynx, tear glands, Eustachian tubes, thyroid gland, parathyroid glands, pituitary gland, pineal gland, and choroid plexus share the same brain relays.

**BIOLOGICAL CONFLICT:** The biological conflict linked to the tear glands is a “morsel conflict”, specifically, a conflict related to a “visual morsel” (see also choroid, iris, and ciliary body).

In line with evolutionary reasoning, morsel conflicts are the primary conflict theme associated with brainstem-controlled organs deriving from the endoderm.


### RIGHT TEAR GLAND



Equivalent to the right half of the mouth and pharynx, the right tear gland correlates to an “ingoing morsel” and to “not being able to catch a visual morsel” because the morsel was ignored by someone else. For example: A child has set eyes on a toy and expects to get it but the parents ignore it, hence, it could not grab the “visual morsel”; a child wants to see his friends or wants to watch TV but the parents don’t allow it; a woman draws her husband’s attention to a ring in a window of a jewellery shop and anticipates getting the ring, but he disregards the “visual morsel” she desires.

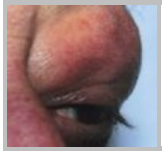### LEFT TEAR GLAND

Equivalent to the left half of the mouth and pharynx, the left tear gland relates to an

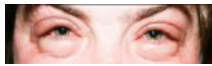

"outgoing morsel" and to "not being able to eliminate a visual morsel" because the morsel was ignored by someone else. For example: A painter wants to sell his paintings but no one takes notice of them; a real estate agent is unable to sell a property, a salesman is left with his products; a person wants to get rid of "morsels" at a garage sale but no one shows up; due to a cancellation a lecturer is unable to share his presentation; a child shows its mother a drawing but she pays no attention.

**CONFLICT-ACTIVE PHASE:** Starting with the DHS, during the conflict-active phase cells in the tear gland proliferate causing an enlargement of the lacrimal gland. The biological purpose of the cell increase is to enhance the production of tear fluid so that the "visual morsel" can be better absorbed (right tear gland) or expelled (left tear gland). Thus, the affected eye is teary and watering (see also nasolacrimal ducts and conjunctiva).



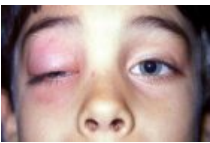With continuing, intense conflict activity (hanging conflict) a cauliflower-shaped growth (secretory type) forms in the tear gland. A large swelling ("lacrimal gland tumor") bulges the eyelid outwards, as shown in this picture.



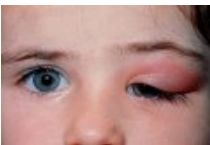**NOTE:** Baggy eyes are related to the kidney collecting tubules and an active abandonment and existence conflict. The skin beneath the eyes is very thin; this is why the water retention is more noticeable in that area.

**HEALING PHASE:** Following the conflict resolution (CL), fungi or mycobacteria such as TB bacteria remove the cells that are no longer needed. Healing symptoms are swelling of the tear gland caused by the edema (fluid accumulation) and purulent eye discharge. In PCL-B, the sticky pus dries up showing as yellowish eye crust around the eye(s). In conventional medicine, agglutinated and crusty eyelids are associated with "allergies" (see conjunctivitis).

The healing phase might be accompanied by an inflammation (dacryoadenitis) with redness and painful swelling of the lacrimal gland. With the SYNDROME, that is, with water retention as a result of an active abandonment and existence conflict, the swelling increases even more. The condition occurs quite often in children.

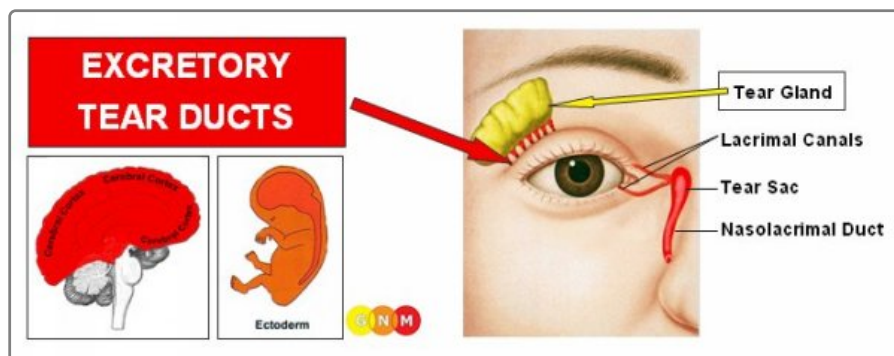


**RIGHT eye:** not being able to catch a visual morsel



**LEFT eye:** not being able to eliminate a visual morsel

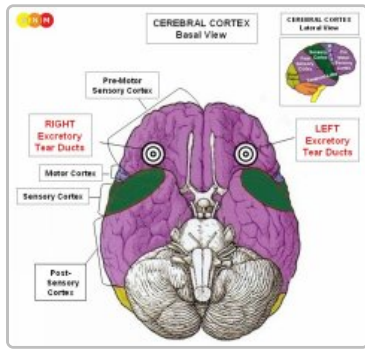
With a hanging healing due to constant conflict relapses more and more tear gland tissue is lost resulting in a decreased tear flow or a complete cessation of tear fluid production. The drying-up of the lacrimal flow (xerophthalmia) is termed Sjogren's or Sicca syndrome (see also dry eyes related to the excretory tear ducts, eyelid gland ducts, conjunctiva, and Sjogren's associated with a dry mouth).



Biological Conflict    Conflict-Active Phase    Healing Phase

**DEVELOPMENT AND FUNCTION OF THE TEAR DUCTS:** The excretory tear ducts release the tear fluid produced by the tear glands into the top part of the conjunctiva and to the outer surface of the eyes. The lacrimal canals, which are

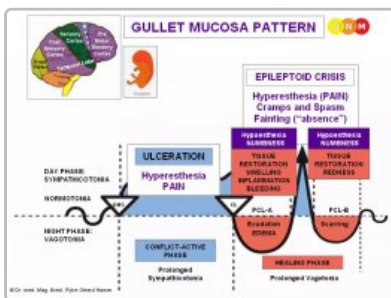
two curved tubes located at the inner border of each eyelid, drain excess tears into the tear sac and through the nasolacrimal duct into the nasal cavity. The lining of the tear ducts consist of **squamous epithelium**, originates from the **ectoderm** and is therefore controlled from the cerebral cortex.



**BRAIN LEVEL:** The epithelial lining of the tear ducts is controlled from the **premotor-sensory cortex** (part of the cerebral cortex). The right tear ducts are controlled from the left side of the cortex; the left tear ducts are controlled from the right cortical hemisphere (fronto-lateral-basal). Hence, there is a cross-over correlation from the brain to the organ.

**NOTE:** The control centers are located closely to the brain relays of the eyelid gland ducts.

**BIOLOGICAL CONFLICT:** Similar to a **separation conflict**, the **biological conflict** linked to the tear ducts is “**wanting to be seen**” (not being noticed or overlooked, feeling visually ignored, not allowed to be seen) or “**not wanting to be seen**” (wanting to be invisible; a fear of getting caught, let’s say, in a criminal act, a sexual act, or when cheating).



The Biological Special Program of the tear ducts follows the **GULLET MUCOSA PATTERN** with hypersensitivity during the conflict-active phase and the Epileptoid Crisis and hyposensitivity in the healing phase.

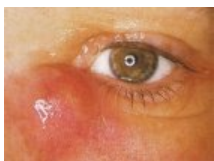**CONFLICT-ACTIVE PHASE:** **ulceration in the epithelial lining of the tear ducts** proportional to the degree and duration of conflict activity. The **biological purpose of the cell loss** is to widen the ducts in order to increase the tear flow. The “shiny eyes” makes the one who has been overlooked more eye-catching (in Nature, this is vital to attract a mate). **Symptoms** are **teary eyes** and potentially painful pulling in the affected tear duct. With an acute conflict the tearing could be excessive (see also watery eyes related to the **tear glands** and the **conjunctiva**).

**HEALING PHASE:** During the first part of the **healing phase (PCL-A)** the tissue loss is replenished through **cell proliferation** with **swelling** due to the **edema** (fluid accumulation) in the healing area. Depending on the intensity of the conflict-active phase, the swelling could lead to an **obstruction of the tear ducts** causing **dry eyes**. A chronic condition because of continual **conflict relapses** is called **Sjogren’s** or **Sicca syndrome** (see also dry eyes related to the **tear glands**, **eyelid gland ducts**, **conjunctiva**), and Sjogren’s associated with a **dry mouth**). However, in this case, Sjogren’s is not preceded by a swelling of the **tear glands**. An occlusion of the excretory tear ducts leads to an enlargement of the entire **tear gland**. The swelling is therefore frequently misdiagnosed as a **lacrimal gland tumor**.

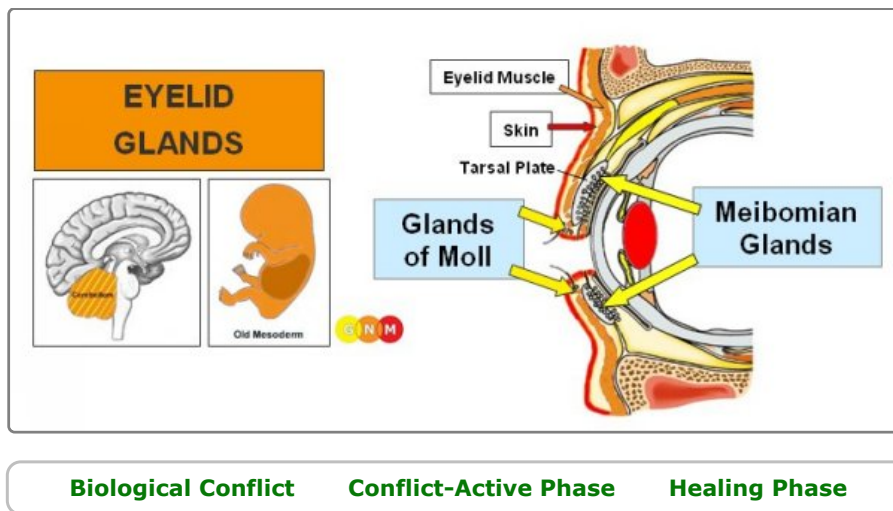
**NOTE:** Whether the tear ducts of the right or left eye are affected is determined by a person’s **handedness** and whether the conflict is **mother/child** or **partner**-related.

Blocked tear ducts are quite common in infants. In infants and newborns the condition reveals the distress of “wanting to be seen” (not getting enough attention) or “not wanting to be seen” (too many visitors stopping by to see the new baby).

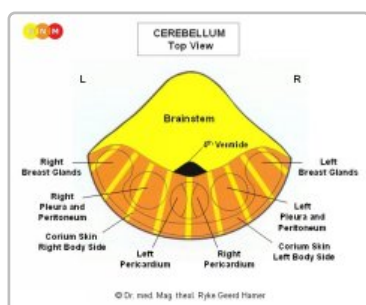
If the **nasolacrimal ducts** are blocked, tears cannot empty into the nasal cavity. The back-up of tears results in **watery and teary eyes**. An obstruction of the nasolacrimal duct with swelling and redness in the area between the eye and the nose, including the lacrimal sac, is called **dacryocystitis** (“tear sac **infection**”).



This picture shows a child with a large swelling of the left nasolacrimal duct. If the child is **right-handed**, this indicates that the **conflict** (wanting to be seen or not wanting to be seen) was associated with the mother but has now been resolved. With concurrent **water retention** (the **SYNDROME**) due to an active **abandonment conflict** the swelling increases considerably.



**DEVELOPMENT AND FUNCTION OF THE EYE LID GLANDS:** The eyelids are movable folds of skin that cover and protect the eyes. The eyelashes attached to the upper and lower eyelids form a second protective shield against dust and other elements that could injure the eye. The outermost layers of the eyelid consist of epidermal tissue (**outer skin**) and **fat tissue**. Two **eyelid muscles** allow the opening and closing of the eyelids. The inside of the lids are lined with the **conjunctiva**. The main function of the eyelids is to keep the front surface of the eyeball and **cornea** moist. The **meibomian glands**, or tarsal glands, are a special type of oil-producing **sebaceous glands** located at the rim of the upper and lower eyelids inside the tarsal plate. Close to the base of the eyelashes are also **sweat glands**, called the **glands of Moll** (both the sebaceous glands and sweat glands are embedded in the **corium skin**). The **excretory ducts of the eyelid glands** carry the oily sebum into the tear film to lubricate the eye during blinking. The eyelid glands originate from the **old mesoderm** and are therefore controlled from the cerebellum.



**BRAIN LEVEL:** In the **cerebellum**, the right eyelid glands are controlled from the left side of the brain; the left eyelid glands are controlled from the right brain hemisphere. Hence, there is a cross-over correlation from the brain to the organ.

**NOTE:** The eyelid glands are embedded in the **corium skin** of the eye. They are therefore controlled from the same brain relays.

**BIOLOGICAL CONFLICT:** The **biological conflict** linked to the eyelid glands is an attack conflict, specifically, an **attack against the eye** (see also **corium skin**).

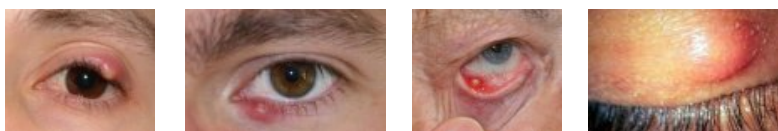
In line with evolutionary reasoning, **attack conflicts** are the primary conflict theme associated with **cerebellum-controlled organs** deriving from the **old mesoderm**.

Dust, sand, or other particles (or a bug) hitting the eye can be registered as an attack conflict. In a figurative sense, the "attack" could be triggered by an insulting look (the "evil eye") or a look of approach. The conflict also relates to **feeling disfigured, soiled or "dirty" concerning the eyelids**. A "yucky" touch or kiss on the eye(s) might activate the conflict. Buying into the theory that touching the eyes after contact with a person who has a **cold** causes an "eye infection" only creates a predisposition for the conflict.

**CONFLICT-ACTIVE PHASE:** Starting with the **DHS**, during the **conflict-active phase** cells in the eyelid glands proliferate proportionally to the intensity of the conflict. The **biological purpose of the cell increase** is to provide an external reinforcement in order to protect the eyelid against further "attacks". If the conflict persists, a **bulb-shaped growth** forms at the site, possibly diagnosed as an **eyelid tumor** (compare with a **melanoma** of the eyelid involving the **corium skin**).

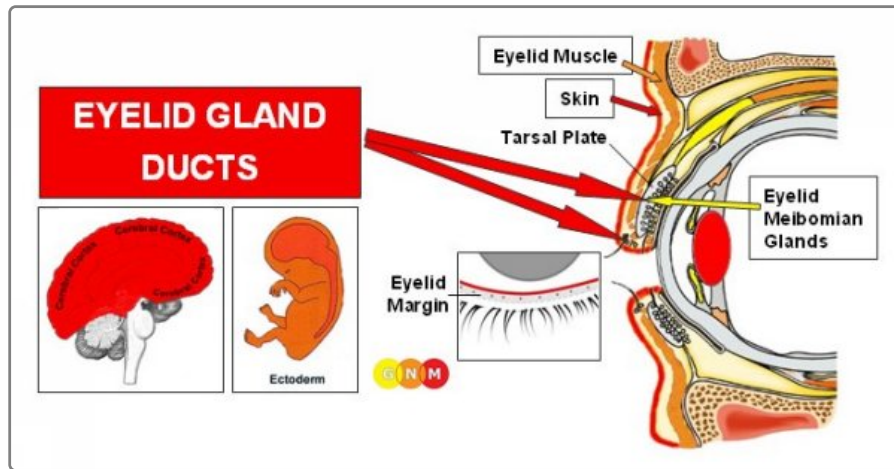
**HEALING PHASE:** Following the **conflict resolution (CL)**, **fungi or bacteria** remove the cells that are no longer needed. During the healing process, the affected area swells up causing what is referred to as a **stye** (hordeola). The painful sore is **red and filled with pus**.

**NOTE:** Whether the right or left eyelid is affected is determined by a person's **handedness** and whether the conflict is **mother/child or partner-related**. A **localized conflict** affects the eye that was associated with the "attack".



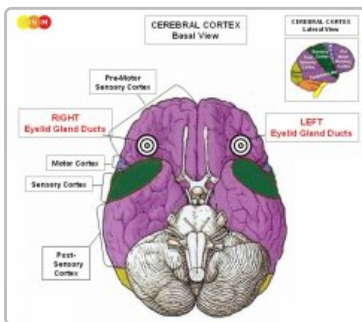
**External styes** involve the **glands of Moll**. They develop on the upper or lower lid margin at the base of the eyelashes. **Internal styes** relate to the **meibomian glands** and occur on the inside of the eyelid. If the meibomian glands become blocked and inflamed this results in a so-called **chalazion** (see right picture above), presenting as a granuloma that typically forms inside the upper eyelid. A chalazion is usually an indication of a **hanging healing** due to frequent **conflict relapses**. **Feeling disfigured** because of the appearance of the style prolongs the healing phase.

**If the required microbes are not available** at the time, the additional cells remain. Eventually, the growth becomes encapsulated with connective tissue.



**Biological Conflict**    **Conflict-Active Phase**    **Healing Phase**

**DEVELOPMENT AND FUNCTION OF THE EYELID GLAND DUCTS:** The excretory ducts of the **eyelid glands** are located along the margin of the eyelid. They carry the oily substance (sebum) produced in the meibomian glands into the tear film to keep the eyes moist and prevent tears from evaporating too quickly. The eyelid gland ducts consist of **squamous epithelium**, originate from the **ectoderm** and are therefore controlled from the cerebral cortex.

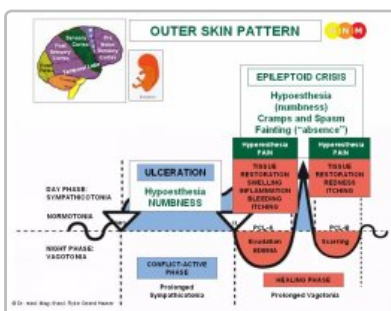


**BRAIN LEVEL:** The epithelial lining of the eyelid gland ducts is controlled from the **pre-motor sensory cortex** (part of the cerebral cortex). The right eyelid ducts are controlled from the left side of the cortex; the left eyelid ducts are controlled from the right cortical hemisphere (fronto-lateral-basal). Hence, there is a cross-over correlation from the brain to the organ.

**NOTE:** The control centers are located closely to the brain relays of the **excretory tear ducts**.

**BIOLOGICAL CONFLICT:** The **biological conflict** linked to the eyelid gland ducts is a **visual separation conflict** experienced as **having lost sight of someone**, for example, of a loved one who has moved away, has left or has died (see also **outer skin of eyelid, conjunctiva, cornea and lens**). The conflict also relates to **not being allowed or not wanting to see someone** (a specific person or certain people). **NOTE:** A visual separation conflict only refers to people and animals such as a pet but not to objects (ring, car, favorite toy) or a home. This would instead involve the **tear glands or the uvea of the eye**.

In line with evolutionary reasoning, **territorial conflicts, sexual conflicts, and separation conflicts** are the primary conflict themes associated with organs of **ectodermal** origin, controlled from the **sensory, pre-motor sensory and post-sensory cortex**.

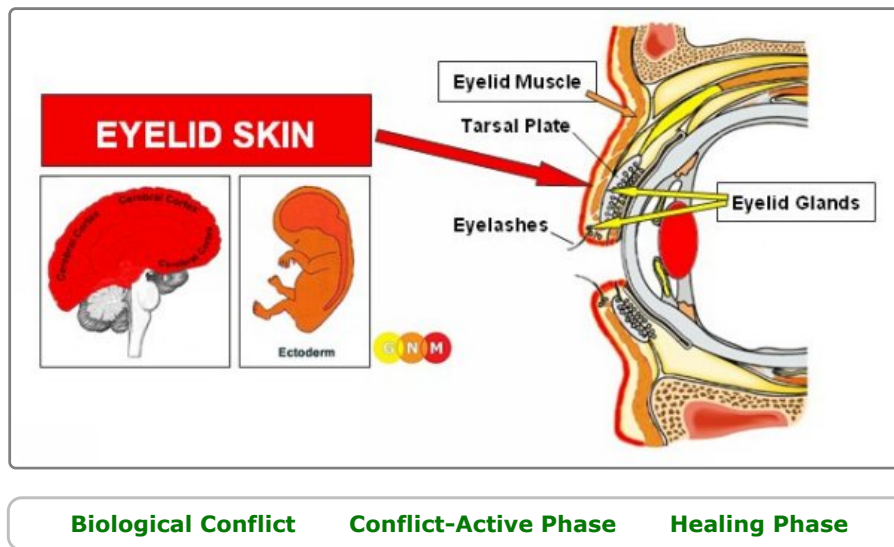


The **Biological Special Program** of the eyelid gland ducts follows the **OUTER SKIN PATTERN** with **hyposensitivity** during the **conflict-active phase** and the **Epileptoid Crisis** and **hypersensitivity** in the **healing phase**.

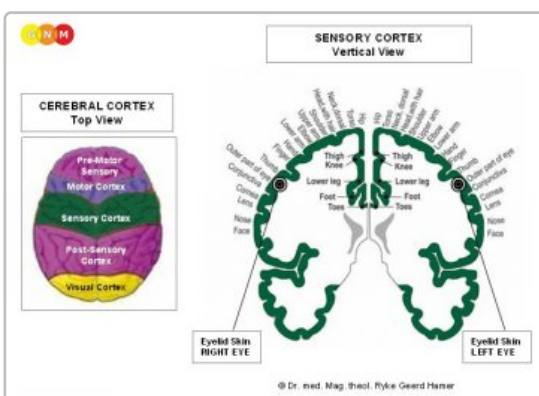
**CONFLICT-ACTIVE PHASE:** ulceration in the eyelid gland ducts proportional to the degree and duration of conflict activity. The **biological purpose of the cell loss** is to widen the ducts to increase the flow of lipids to keep the eye lubricated. In Nature, the clearer vision allows to quickly recognize a new mate that "strikes the eye".

**NOTE:** Whether the ulceration occurs in the right or left eyelid gland ducts is determined by a person's handedness and whether the conflict is mother/child or partner-related.

**HEALING PHASE:** During the first part of the healing phase (PCL-A) the tissue loss is replenished through **cell proliferation** with **swelling** due to the **edema** (fluid accumulation) in the healing area. The swelling might occlude the ducts (called "obstructive meibomian gland disease"). The blockage leads to a thinning of the lipid tear film layer and increased evaporation of tears causing **dry eyes**. If the symptom becomes chronic because of **conflict relapses**, then the condition is termed **Sjogren's** or **Sicca syndrome** (see also dry eyes related to the **tear glands**, **excretory tear ducts**, **conjunctiva**, and Sjogren's associated with a **dry mouth**).



**DEVELOPMENT AND FUNCTION OF THE EYELID SKIN (EPIDERMIS):** The eyelid skin consists of two layers: the **corium skin** containing oil-producing **sebaceous glands** and the outer skin (**epidermis**). The inside of the eyelid is lined with the **conjunctiva**. The outer eyelid skin, which is relatively thin, is supported by the tarsal plate to which the **eyelid muscles** are attached. The outer skin of the eyelid consists of **squamous epithelium**, originates from the **ectoderm** and is therefore controlled from the cerebral cortex.

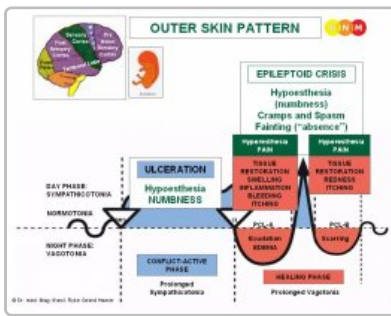


**BRAIN LEVEL:** The eyelid skin (epidermis) is controlled from the **sensory cortex** (part of the cerebral cortex). The right eyelid skin is controlled from the left side of the sensory cortex; the left eyelid skin is controlled from the right cortical hemisphere. Hence, there is a cross-over correlation from the brain to the organ.

**BIOLOGICAL CONFLICT:** The **biological conflict** linked to the eyelid skin is a **visual separation conflict**, specifically, **having lost sight of a person while one had the eyes closed**. For example, a loved one left or died unexpectedly while one was asleep; a mother lost sight of her infant while she was dozing off (compare with visual separation conflict related to the **eyelid gland ducts**, **conjunctiva**, **cornea** and **lens**). The skin of the eyelid also relates to a separation conflict (loss of physical contact) of **wanting to be touched on the eyelid** (caressed or kissed) or **not wanting to be touched** there (see **outer skin**). **NOTE:** A visual separation conflict only refers to people and animals such as a pet but not to objects (ring, car, favorite toy) or a home. This would instead involve the **tear glands** or the **uvea of the eye**.

In line with evolutionary reasoning, **territorial conflicts**, **sexual conflicts**, and **separation conflicts** are the primary conflict themes associated with organs of **ectodermal** origin, controlled from the **sensory**, **pre-motor sensory** and **post-sensory cortex**.

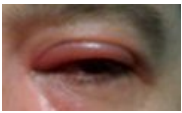**NOTE:** Whether the right or left eyelid is affected is determined by a person's **handedness** and whether the conflict is **mother/child** or **partner**-related.



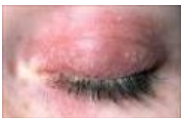The **Biological Special Program** of the eyelid skin follows the **OUTER SKIN PATTERN** with hyposensitivity during the conflict-active phase and the Epileptoid Crisis and hypersensitivity in the healing phase.

**CONFLICT-ACTIVE PHASE:** ulceration in the epithelial lining of the eyelid skin proportional to the degree of conflict activity. The ulcerative process makes the **eyelid skin dry and flaky**. The **Biological Special Program** of the **outer skin** is always accompanied by a **short-term memory loss**, which serves the purpose to forget temporarily the one who is absent, here, specifically, the one who is out of sight.

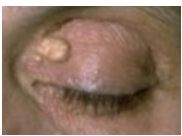**HEALING PHASE:** During the **healing phase** (in PCL-A the ulcerated area is replenished with new cells. With an inflammation the condition is called **blepharitis**. The symptoms, including swelling, redness, a burning sensation and itching, range from mild to severe, depending on the intensity of the conflict-active phase.



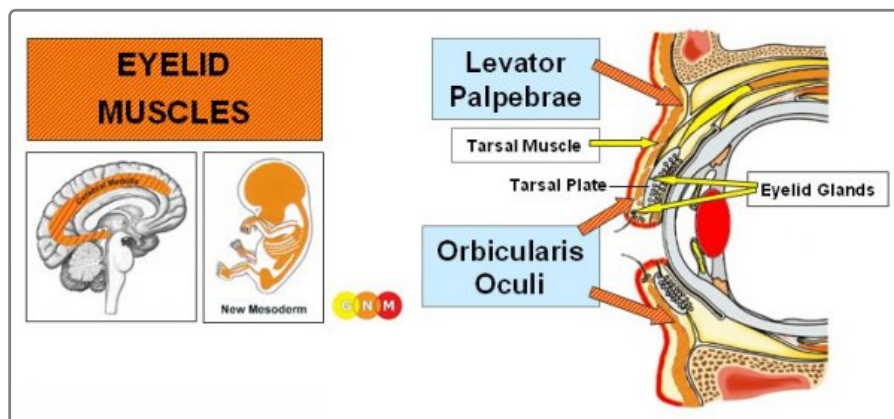
This picture shows blepharitis on the left eye, indicating the healing of a **visual separation conflict** associated with a **partner**, if the person is **left-handed**. For a right-hander the conflict relates to his/her **mother or child**.



The healing process might also present as a **rash on the eyelid (eyelid dermatitis)**.



A fat nodule on the eyelid, called a **xanthelasma**, is linked to a **self-devaluation conflict** associated with the eye (see **fat tissue**).

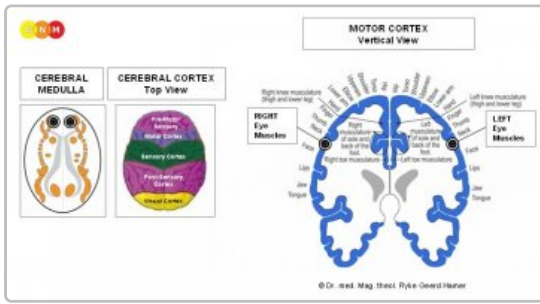


**Levator Palpebrae Muscle**

**Orbicularis Oculi Muscle**

**DEVELOPMENT AND FUNCTION OF THE EYELID MUSCLES:** The eyelids contain three main muscles that control the movement of the eyelid. The two muscles involved in opening the upper eyelid are the **levator palpebrae muscle** (for voluntary opening) and the **tarsal muscle** (for involuntary opening). The **orbicularis oculi muscle** in the upper and lower eyelid controls the closing of the eye. As the eye elevates the levator muscle contracts and raises the eyelid; when the levator relaxes, the eyelid closes passively. Active eyelid closure to protect the eyes from injury and from excessive light (see **pupil muscles**) is achieved by the contraction of the orbicularis oculi. The eyelid muscles also control the blink reflexes. Blinking provides moisture to the eyes and the **cornea** by using tears (produced in the **tear glands**) and oily substances (secreted by the **eyelid glands**) to keep it from drying out. The eyelid muscles are attached to the tarsal plate that gives the lids shape and strength. Underneath and within the tarsal plate lie the **meibomian**

**glands.** The levator palpebrae and orbicularis oculi consist of **striated muscles**, originate from the **new mesoderm** and are controlled from the cerebral medulla and the motor cortex.



**BRAIN LEVEL:** The levator palpebrae and orbicularis oculi have two control centers in the cerebrum. The trophic function of the muscles, responsible for the nutrition of the tissue, is controlled from the **cerebral medulla**; the ability to move the eyelids is controlled from the **motor cortex** (part of the cerebral cortex).

The eyelid muscles of the right eyelid are controlled from the left side of the cerebrum; the eyelid muscles of the left eyelid are controlled from the right cerebral hemisphere. Hence, there is a cross-over correlation from the brain to the organ.

The smooth tarsal muscle is controlled from the **midbrain**.

## LEVATOR PALPEBRAE MUSCLE

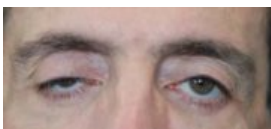**BIOLOGICAL CONFLICT:** The **biological conflict** linked to the levator palpebrae muscle is **not being able to keep the eye(s) open** (because of extreme fatigue, working night shifts) or **not having kept the eye(s) open** (having been wide awake) **at the right time** (having missed a red traffic light or an important visual message, e.g., on a blackboard or screen; having overlooked something of importance such as the small print of a contract). Certain professions, for example, policemen, detectives, pilots, professional drivers, people attending monitors and other devices used for observation are more susceptible to suffer this type of conflict. The levator muscle also relates to **not being allowed to keep the eye(s) open** (being prohibited to see or watch something) or **not wanting to keep the eye(s) open** (wanting to avoid seeing something distressing).

**NOTE:** Whether the levator muscle of the right or left eyelid is affected is determined by a person's **handedness** and whether the conflict is **mother/child** or **partner**-related.

**CONFLICT-ACTIVE PHASE:** **cell loss (necrosis) of the levator palpebrae** (controlled from the cerebral medulla) and, proportional to the degree of conflict activity, increasing **paralysis of the levator muscle** (controlled from the motor cortex).

**NOTE:** The **striated muscles** belong to the group of organs that respond to the related conflict not with cell proliferation or cell loss but with functional loss (see also **Biological Special Programs** of the islet cells of the pancreas (**alpha islet cells** and **beta islet cells**), inner ear (**cochlea** and **vestibular organ**), **olfactory nerves**, **retina** and **vitreous body of the eyes**) or hyperfunction (**periosteal nerves** and **thalamus**). In case of the striated muscles, the conflict-active phase manifests as **muscle paralysis**. From a biological point of view, the paralysis is an innate fake-death reflex in response to danger.

Because of the weakness or paralysis of the levator muscle, responsible for raising the eyelid, the **upper eyelid sags** and fails to fully open. Depending on the intensity of the conflict, the droop may be barely noticeable or the eyelid can descend over the entire pupil. Yet, the eyelid doesn't close to cover the eye completely since the **tarsal muscle** prevents a complete closing. In medical terms, a drooping eyelid is called **blepharoptosis** (or **ptosis**). The inability to fully close the eyelid is termed **lagophthalmos**.



If the right upper eyelid droops, as seen in this image, the conflict is **partner**-related provided the person is **right-handed**.

**HEALING PHASE:** During the **healing phase** the levator muscle is reconstructed; the paralysis reaches into **PCL-A**. The **Epileptoid Crisis** manifests as eyelid muscle spasms (**blepharospasm**). Depending on the degree of the **conflict-active phase**, the rapid movement of the eyelid ranges from minor **eyelid fluttering** to strong **eyelid twitching or eyelid tics** (compare with **facial tics**). In **PCL-B** the function of the eyelid muscle returns to normal.

**Excessive eye blinking** also involves the levator muscle. The explicit **conflict linked to the blink reflex** is **feeling sussed out or figured out**, for example, when someone was caught cheating, lying, or playing tricks. The rapid blinking occurs during the **Epileptoid Crisis** and is typically triggered when setting on a **track**, for example, when the person is telling a lie.

## ORBICULARIS OCULI MUSCLE

**BIOLOGICAL CONFLICT:** The **biological conflict** linked to the orbicularis oculi muscle is **not being able to close the eyes** (in order to avoid seeing something unpleasant or undesirable; wanting to turn a "blind eye" to something) or **not having closed the eyes at the right time** (accidents caused by exposure to fire or explosives or by unsafe work with a welding device). The orbicularis oculi also relates to **not being allowed to close the eyes** (not being permitted to sleep or not getting enough sleep, for example, mothers with newborns, students working on last-minute term papers, shift workers, long-distance truck drivers) or **not wanting to close the eyes** (kids refusing to nap).

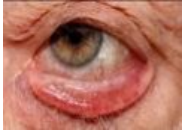**NOTE:** Whether the orbicularis muscle of right or left eyelid is affected is determined by a person's **handedness** and whether the conflict is **mother/child** or **partner**-related.



**CONFLICT-ACTIVE PHASE:** cell loss (necrosis) of the orbicularis oculi of the upper or lower eyelid (controlled from the cerebral medulla) and, proportional to the degree of conflict activity, increasing **paralysis of the orbicularis oculi muscle** (controlled from the motor cortex).

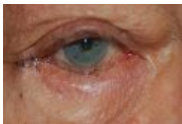
**NOTE:** The **striated muscles** belong to the group of organs that respond to the related conflict not with cell proliferation or cell loss but with functional loss (see also **Biological Special Programs** of the islet cells of the pancreas (**alpha islet cells** and **beta islet cells**), inner ear (**cochlea** and **vestibular organ**), **olfactory nerves**, **retina** and **vitreous body** of the eyes) or hyperfunction (**periosteal nerves** and **thalamus**). In case of the striated muscles, the conflict-active phase manifests as **muscle paralysis**. From a biological point of view, the paralysis is an innate fake-death reflex in response to danger.

Because of the weakness or paralysis of the orbicularis oculi muscle, responsible for closing the eyelid, the upper and lower **eyelid cannot be closed properly** (see also **facial paralysis** with the inability to close the eye on the paralyzed side. The orbicularis oculi and the facial muscles are both supplied by the facial nerve).

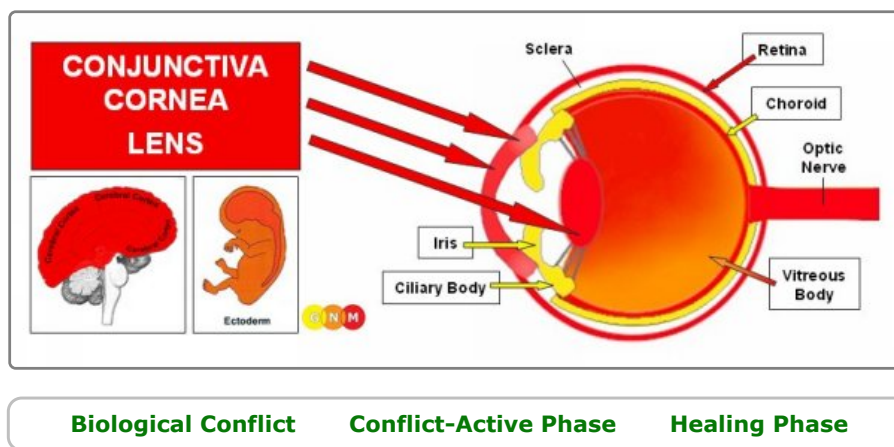


If the **lower eyelid** is affected, the **decreased tension** of the orbicularis oculi causes the lower lid to sag outwards, away from the eye. This condition is known as an **ectropion** (see picture). If the upper eyelid is affected, the **upper eyelid droops** (compare with **ptosis** related to the biological conflict of the **levator palpebrae muscle**).

**HEALING PHASE:** During the **healing phase** the orbicularis oculi muscle is reconstructed; the paralysis reaches into PCL-A. The **Epileptoid Crisis** manifests as eye muscle spasms (**blepharospasm**) of the upper or lower eyelid. Depending on the degree of the conflict-active phase, the rapid movement of the eyelid ranges from minor **eyelid fluttering** to strong **eyelid twitching or eyelid tics** (see also **facial tics**). In PCL-B the function of the eyelid muscle returns to normal.

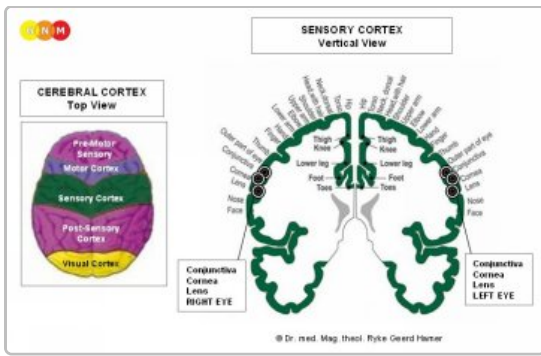


With a **hanging healing** due to continual **conflict relapses** the prolonged **increased tension** of the orbicularis oculi of the **lower eye lid** causes the eyelid to fold inwards. This condition, called an **entropion**, is quite uncomfortable since the eyelashes constantly rub against the eye leading to redness and irritation of the eye.



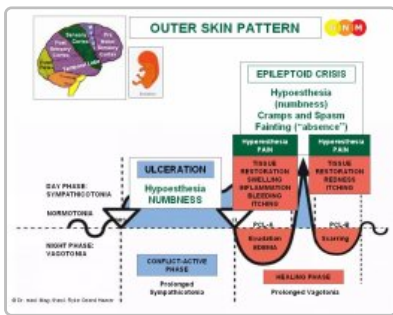
**DEVELOPMENT AND FUNCTION OF THE CONJUNCTIVA, CORNEA, AND LENS:** The **conjunctiva** is a clear mucous membrane that lines the sclera (the white of the eye) and the inside of the **eyelid**. The main function of the conjunctiva is to produce tears to keep the front surface of the eyeball moist. The larger volume of tear fluid, however, is secreted by the **tear glands**. The **cornea** is a transparent structure that covers the **iris** and the **pupil**. The cornea controls the entry of light into the eyes. When light strikes the cornea it refracts the incoming light onto the lens that refocuses the light onto the **retina**. The crystalline **lens** is located behind the iris and held in place by the **ciliary muscles** that allow to alter the shape of the lens in order to get sharp images of objects at various distances. Both the cornea and the lens are responsible for the eye's focusing power and for fine-tuning the vision process. The conjunctiva, cornea, and lens consist of **squamous epithelium**, originate from the **ectoderm** and are therefore controlled from the cerebral cortex.

**BRAIN LEVEL:** The conjunctiva, cornea, and lens are controlled from the **sensory cortex** (part of the cerebral cortex). The conjunctiva, cornea, and lens of the right eye are controlled from the left side of the sensory cortex; the conjunctiva, cornea, and lens of the left eye are controlled from the right cortical hemisphere. Hence, there is a cross-over correlation from the brain to the organ.



**BIOLOGICAL CONFLICT:** The biological conflict linked to the conjunctiva, cornea, and lens is a **visual separation conflict** of **having lost sight of someone**, for example, of a loved one who has moved away, left, or has died (see also **eyelid gland ducts** and **outer skin of eyelid**). This includes having lost sight of a pet. The conflict also relates to **not being allowed to see someone** (a grandchild, a lover, a friend, a school mate, a relative in the hospital) or **not wanting to see someone** (“get out of my sight!”). The fear of not being able or not being permitted to see a certain person might already trigger the conflict. The degree of the conflict determines which one of the three tissues will be affected by the DHS. The conjunctiva is associated with a moderate visual separation conflict, the cornea with a more severe conflict; the lens is affected when the conflict is experienced as very intense. **NOTE:** A visual separation conflict only refers to people and animals such as a pet but not to objects (ring, car, favorite toy) or a home. This would instead involve the **tear glands** or the **uvea of the eye**.

In line with evolutionary reasoning, **territorial conflicts**, **sexual conflicts**, and **separation conflicts** are the primary conflict themes associated with organs of **ectodermal** origin, controlled from the **sensory, pre-motor sensory and post-sensory cortex**.




The **Biological Special Program** of the conjunctiva, cornea, and lens follows the **OUTER SKIN PATTERN** with **hyposensitivity** during the conflict-active phase and the **Epileptoid Crisis** and **hypersensitivity** in the healing phase.

**CONFLICT-ACTIVE PHASE:** **ulceration in the conjunctiva, cornea, or lens**. In the lens, the **loss of crystalline cells** improves the reception of light and therefore the visual acuity with the **biological purpose** that the person fading from one’s sight will be longer visible. The enhanced distant vision also increases the chance of detecting a lost “pack member” in the far distance. The **Biological Special Programs** of the conjunctiva, cornea, and lens are accompanied by a **short-term memory loss**, which serves the purpose to forget temporarily the one who is out of sight (see **separation conflict** related to the **skin**).

**NOTE:** Whether the conjunctiva, cornea, or lens of the right or left eye is affected is determined by a person’s **handedness** and whether the conflict is **mother/child** or **partner**-related.

In the **conjunctiva**, the **ulceration makes the eye(s) dry** (see also dry eyes related to the **tear glands**, **excretory tear ducts**, and **eyelid gland ducts**).

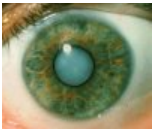


In the **cornea**, the prolonged ulceration leads to a so-called **keratoconus** in which the normally round cornea becomes thin and begins to bulge into a cone-like shape. The asymmetrical, unequal shape of the cornea causes **astigmatism** with **distorted and double vision** (see also **healing phase**). Typical is a constant blur for both near and distant vision. Because of the cornea’s function to refract light, people with astigmatism are **light sensitive**.

If the cornea’s angle of curvature becomes too steep, this causes **nearsightedness** or **myopia** (see also **smooth ciliary muscles** and **retina**). **Farsightedness** or **hyperopia** occurs when the cornea has too flat of an angle (see also **striated ciliary muscles** and **retina**).

**HEALING PHASE:** During the **healing phase** the cell loss is restored and replenished.

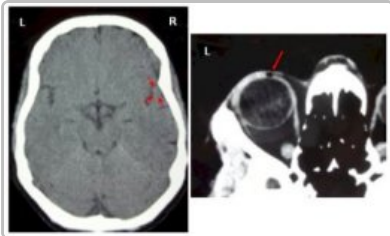
Concerning the **lens**, the healing process manifests as **clouding of the lens** with a **fuzzy or hazy vision** (there are no symptoms in the conflict-active phase). If the healing phase cannot be complete because of continuous **conflict relapses**, the clouding remains (see picture). A permanent opacity of the lens is called a **“grey cataract”** (compare with “green cataract” related to the



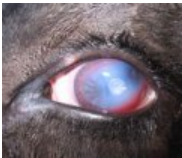vitreous body).

According to conventional medicine, cataracts are considered a normal part of the aging process even though not every person develops a cataract at an older age. From a GNM point of view, it is rather the increasing incidences of **visual separation conflicts** – from a parent, a spouse, a long-time companion or friend – why cataracts are much more common in older people.

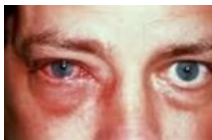In the **cornea**, the healing symptom presents as **clouding of the cornea**. With an inflammation the condition is called **keratitis**. The symptoms include pain, redness and blurry vision. With constant **conflict relapses** the **astigmatism** (see **conflict-active phase**) becomes permanent due to recurrent scarring processes in the cornea.



In the left image we see a **Hamer Focus** (in **PCL-A**) on the right side of the sensory cortex in the area that controls the cornea of the left eye (view the **GNM diagram**). A look at the orbit section (right image) confirms that a healing process in the cornea (red arrow) is under way.

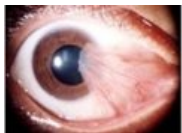


This picture shows a dog with keratitis in the left eye. If the dog is **left-pawed**, this indicates that the **visual separation conflict** is linked to a "**partner**" such as his master or another dog or animal friend.

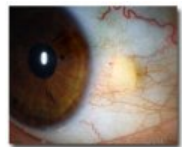


**Conjunctivitis (pink eye)** with red, burning, itchy, and watery eyes occurs when the **conjunctiva** is in healing (see also watery eyes related to the **tear glands** or **nasolacrimal ducts**). The inflammation often involves the inside of the **eyelids** (compare with **blepharitis** related to the **eyelid skin**). The symptoms range from mild to severe, depending on the intensity of the **conflict-active phase**. For a **right-handed** person, the right eye is affected if the **visual separation conflict** is associated with a **partner**; if the person is **left-handed** the conflict is **mother/child-related**.

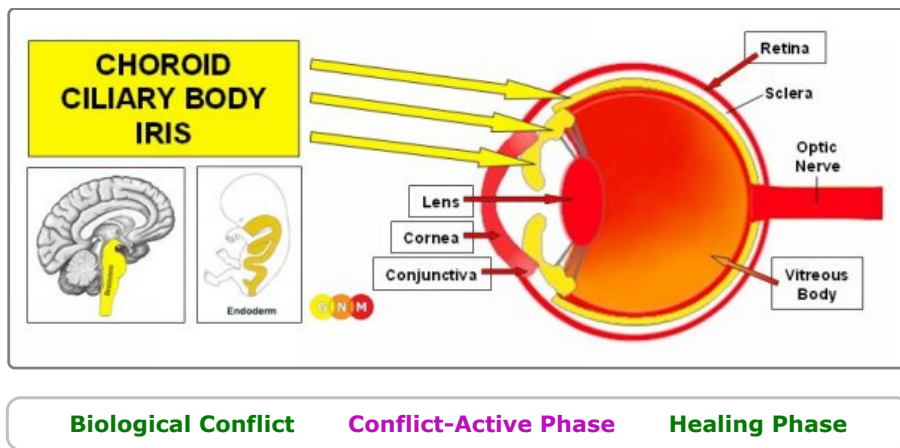
Conjunctivitis is commonly associated with "**allergies**" and assumed to be caused by the exposure to pollen. With concurrent cold symptoms such as a **runny nose**, the "**allergy**" is called "**hay fever**". In GNM terms, the combination of the symptoms is a sign that the healing phase of a **visual separation conflict** and of "**scent or stink conflict**" related to the **nasal mucosa** happen simultaneously. Agglutinated and crusty eyelids reveal that an additional "**visual morsel conflict**" involving the **tear glands** has also been resolved.



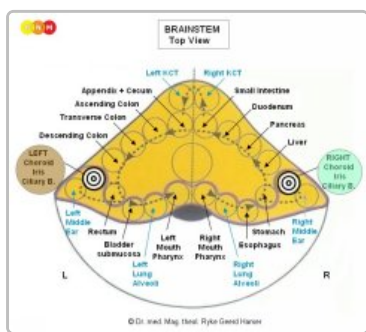
A so-called **pterygium** is the result of a prolonged healing process (**hanging healing**) with a buildup of scar tissue that grows from the conjunctiva towards the center of the eye onto the cornea.



A **pinguecula** ("eye bump") is a yellowish or white patch growing on the conjunctiva, also a result of a **hanging healing** due to continuous **conflict relapses**. Unlike a pterygium, the growth does not reach into the cornea.



**DEVELOPMENT AND FUNCTION OF THE CHOROID, IRIS, AND CILIARY BODY:** The choroid, iris, and ciliary body are collectively called the uvea. The **choroid** lines the inner surface of the eyeball and supplies the overlying **retina** with nutrition. The **iris** in the front of the eye is part of the choroid. The iris helps to regulate the amount of light that enters the eye (see also **cornea**) and is therefore functionally closely tied to the **pupils**. The **ciliary body** connects the choroid with the iris. The ciliary body produces a watery fluid to keep the eye moist and secretes a gel-like substance which fills the **vitreous body**. It also contains the **ciliary muscles** that control the shape of the **lens** to allow clear vision. The uvea contains considerable amounts of melanin pigments to protect the eye from excess light (see also **corium skin**). In the iris, the quantity of melanin determines the color of the iris ranging from brown to blue. In evolutionary terms, the choroid, iris, and ciliary body constitute the **primordial eye cup** that developed from the intestinal mucosa of the original **gullet** (see also **pupil muscles** and **ciliary muscles**). Like the **intestinal cells** and digest the "food morsel", the biological function of the uvea is to "absorb" (**resorptive quality**) and to "digest" (**secretory quality**) the "visual morsel". The choroid, iris, and ciliary body consist of **intestinal cylinder epithelium**, derive from the **endoderm** and are therefore controlled from the brainstem.



**BRAIN LEVEL:** In the **brainstem**, the choroid, iris, and ciliary body have two control centers that are positioned in close vicinity to the brain relays that control the organs of the **alimentary canal**.

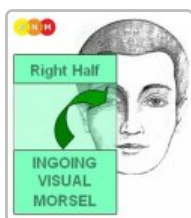
The choroid, iris, and ciliary body of the right eye are controlled from the right side of the brainstem; the choroid, iris, and ciliary body of the left eye are controlled from the left brainstem hemisphere. There is no cross-over correlation from the brain to the organ.

**NOTE:** The **optic nerve** emerged from the brain relays that innervated the primordial eyecup (today's choroid).

**BIOLOGICAL CONFLICT:** The **biological conflict** linked to the choroid, iris, and ciliary body is a "**morsel conflict**", specifically, a conflict related to a "**visual morsel**" (see also **tear glands**).

In line with evolutionary reasoning, **morsel conflicts** are the primary conflict theme associated with **brainstem-controlled organs** deriving from the **endoderm**.


### UVEA OF THE RIGHT EYE



Equivalent to the **right half of the mouth and pharynx**, the **choroid, iris, and ciliary body of the right eye** correlate to an "**ingoing morsel**" and to "**not being able to catch a visual morsel**".

In biological terms, the ingoing "visual morsel" is equal to nourishment (see also **sound morsel** related to the **middle ear and Eustachian tubes**). Figuratively speaking, the conflict experience is "I want to devour what I desire with my eyes". What one is "drooling" to see can relate to anyone or anything one is not or no longer able to see or not allowed to see, for example, a beloved person or a home one had lost. It might also be about something one had anticipated to see (a certain person, paper money, a toy, a TV program, a vacation resort) and could unexpectedly not visually "grab" or "catch sight of". The fear of becoming blind ("not being able to catch a visual morsel") triggered, for example, by a **MS diagnosis**, a diabetes diagnosis (see **diabetic retinopathy**), or the negative prognosis of a **macular degeneration** could also prompt the conflict.

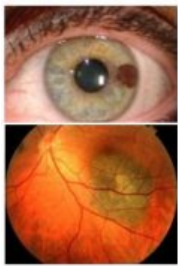### UVEA OF THE LEFT EYE



Equivalent to the **left half of the mouth and pharynx**, the **choroid, iris, and ciliary body of the left eye** correspond to an **“outgoing morsel”** and to **“not being able to eliminate a visual morsel”** (originally, the feces morsel).

Such an undesired “visual morsel” relates to any “eye sore” one wants to get rid of (“I can’t bear the look at it”) or images one wants to erase from one’s memory. Eye-witnessing an accident or crime, seeing a spouse or partner with someone else, or watching something disturbing on TV can activate the conflict. Children suffer the distress when “catching” their parents or witnessing family abuse. The unwanted “visual morsel” could also be a person one does no longer want to see (a relative, parent, ex-spouse, “friend”, colleague, teacher, visitor).

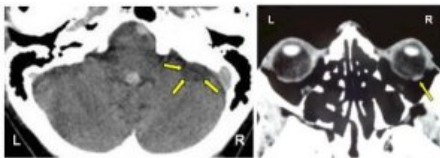
**CONFLICT-ACTIVE PHASE:** Starting with the **DHS**, during the **conflict-active phase** cells in the choroid, iris, and ciliary body proliferate proportionally to the intensity of the conflict. The **biological purpose of the cell increase** is to be better able to absorb (right eye) or expel (left eye) the “visual morsel”. Which one of the tissues is affected is random.



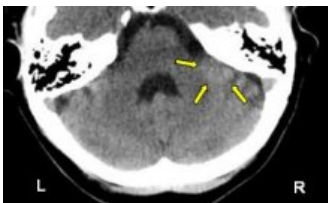
With prolonged conflict activity a flat (**resorptive type**) or compact (**secretory type**) growth develops from the pigmented cells of the uvea. In conventional medicine, this is called a **ciliary body melanoma, iris melanoma** (upper picture) **choroid melanoma** (lower picture). Histologically, the term “melanoma” is actually incorrect since the uvea does not have a **corium skin**; the term “adenoma” would be more applicable. The same pertains to what is called **“retinitis pigmentosa”** which is, according to **Dr. Hamer’s** findings, a condition of the choroid (choroid adenoma) rather than of the retina.

**HEALING PHASE:** Following the **conflict resolution (CL)**, **fungi or mycobacteria** such as TB bacteria remove the cells that are no longer required.

In the **choroid**, the tubercular lesions are visible as white spots behind the retina which; they disappear with the completion of the healing phase. A continuous decomposing process, however, creates **caverns in the choroid** that are eventually filled with calcium deposits. The loss of pigmentation causes **light sensitivity**.

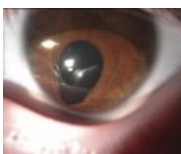


On the left image we see a **brain edema** (in **PCL-A**) on the right side of the brainstem in the area that controls the choroid of the right eye (**view the GNM diagram**). On a brain scan the fluid accumulation presents as dark (hypodense). The orbit section (right image) shows the presence of TB bacteria (yellow arrow).

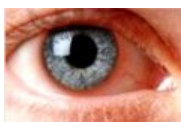

During the second part of the healing phase (in **PCL-B**) **glial cells** proliferate at the site to restore the brain relay where the **visual morsel conflict** was registered. On a brain CT the glia accumulation shows as white (hyperdense). In conventional medicine, the glia buildup is wrongly believed to be a **“brain tumor”**.

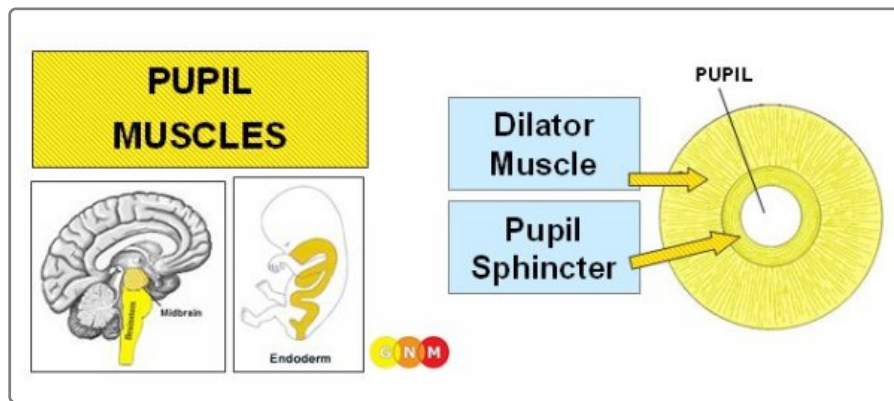
**NOTE:** The optic nerve is a paired nerve that transmits visual information from the **retina** to the **visual cortex** at the back of the brain. It is one of the two cranial nerves (the other being the **olfactory nerve** innervating the **olfactory bulb**) that are a protrusion of the cerebrum. The optic nerves are largely composed of **glial cells**. An enlargement of the optic nerve is therefore referred to as an “optic nerve glioma”, or optic neuroma, which can arise anywhere along the **pathway of the optic nerve**. In GNM terms, an **optic neuroma** that develops in the brainstem (in **PCL-B**) originates from a **“visual morsel” conflict** involving the choroid (compare with **acoustic neuroma** related to a **“sound morsel”** and the acoustic nerve).



In the **iris**, lasting tuberculosis leads eventually to a loss of iris tissue (**coloboma**) with the result that the pupil becomes larger at that area.

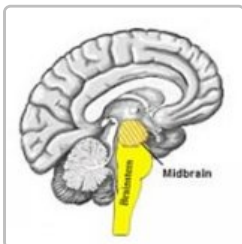


**Iritis** is a painful inflammation of the iris. The condition can occur together with **choroiditis**, an inflammation of the choroid. **Uveitis** involves the entire uvea.



**Biological Conflict    Conflict-Active Phase    Healing Phase**

**DEVELOPMENT AND FUNCTION OF THE PUPIL MUSCLES:** The pupil is the black round hole in the center of the iris. Its blackness is due to the lack of reflection of light from within the eye. The pupils consist of two muscles that regulate the amount of light that enters the eye. The **dilator muscle** widens the pupils allowing more light to pass through the eyes; the **pupil sphincter** narrows the pupils so that less light reaches the retina. In bright light the sphincter muscle contracts while the dilator muscle relaxes, making the aperture smaller. In dim light the sphincter muscle relaxes while the dilator muscle contracts, opening up the aperture. The dilator muscle is supplied by sympathetic nerves, which is why the pupils become large during stress (*sympathicotonia*) or sexual arousal. The pupil sphincter is supplied by parasympathetic nerves making the pupils small during relaxation (*vagotonia*). In evolutionary terms, the pupil muscles belong to the **primordial eye cup** that developed from **intestinal cells** (see also **ciliary muscles** and **ciliary body**). Like the **intestinal muscles** that move the "food morsel" along the intestinal canal through peristaltic motion, the pupil muscles contract and expand in response to the "light morsel". The dilator muscle and pupil sphincter are composed of **smooth muscle**, derive therefore from the **endoderm** and are controlled from the **midbrain**.



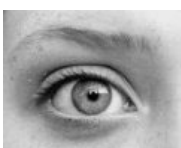**BRAIN LEVEL:** The pupil muscles are controlled from the **midbrain**, located at the outermost part of the brainstem.

**BIOLOGICAL CONFLICT:** According to their function, the pupil muscles are linked to a **light-related morsel conflict** – literally or figuratively.

The **dilator muscle** of the **right pupil** corresponds to the conflict of **"not enough light to catch a morsel"**. This can relate to any important information (on a board or screen), warnings ("watch your step!"), signs (a road sign) or a person that was overlooked because of insufficient light. The **left pupil** correlates to **"not enough light to eliminate a morsel"**, for example, if one is not able to avert a dangerous situation (an accident, an attack) because it was too dark (compare with the distress of sudden long darkness associated with the **pineal gland**). In a figurative sense, the conflict can be provoked if one is unexpectedly not in the "lime light" or not presented in the "proper light".

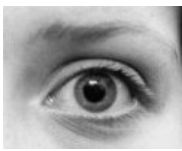The **pupil sphincter** of the **right pupil** corresponds to the conflict of **"too much light to catch a morsel"** (a visual morsel that is of importance), let's say, because one was blinded by the sun or by bright light such as head lights, spotlights, a search light, a (police) flash light, or a welding device. The **left pupil** correlates to **"too much light to eliminate a morsel"**, for example, if one is not able to prevent a dangerous situation because it was too bright. In a figurative sense, the conflict could be triggered when the "spotlight" is turned on someone, bringing something unpleasant or embarrassing "to light".

**CONFLICT-ACTIVE PHASE:**

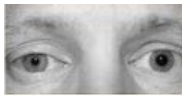

The distress of „too much light“ causes a sustained **hypertonus of the pupil sphincter**. The **biological purpose of the increased muscle tension** is to make the pupil smaller so that less light enters the eye. A prolonged or excessive **constriction of the pupil** is called **myosis**.

The distress of „not enough light“ causes a sustained **hypertonus of the dilator muscle**. The **biological purpose of the increased muscle tension** is to widen the pupil so that more light

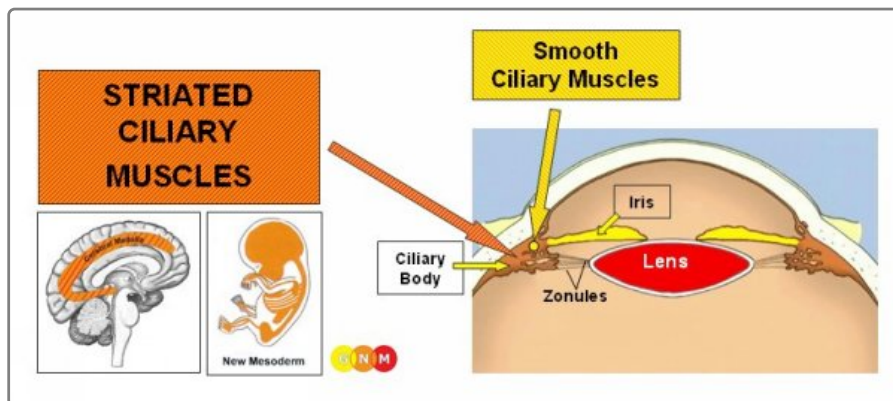


can pass through the eye. A prolonged or excessive **dilation of the pupil** is called **mydriasis**, which causes **light sensitivity**.



An enlargement of the right pupil, as seen in this picture, reveals that the person is conflict active with "not enough light to catch a morsel".

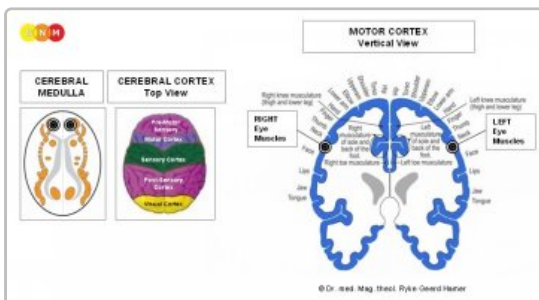
**HEALING PHASE:** During the healing phase the muscle tension goes back to normal. The **Epileptoid Crisis** presents as **pupil spasms** (compare with **fluttering of the lens** and **nystagmus** related to the **extraocular muscles**).



Smooth Ciliary Muscles

Striated Ciliary Muscles

**DEVELOPMENT AND FUNCTION OF THE CILIARY MUSCLES:** The **ciliary body** contains a set of ciliary muscles that regulate the changing of the **lens** shape (accommodation) to produce a clear vision at varying distances. Ligaments called **zonules** connect the ciliary body with the lens to hold it in place. The contraction of the ciliary muscles relaxes the zonules causing the lens to become rounder, which increases its power to focus on nearby objects. When the ciliary muscles relax, the zonules pull the edges of the lens making it flatter to see objects in a far distance. The ciliary muscles are composed of **smooth muscle** (involuntary) and **striated muscles** (voluntary) allowing a sharp focus through squinting. In evolutionary terms, the smooth ciliary muscles belong to the **primordial eye cup** (see **ciliary body** and **pupil muscles**); they therefore originate from the **endoderm** and are controlled from the midbrain. The striated ciliary muscles derive from the **new mesoderm** and are controlled from the cerebral medulla and the motor cortex.



**BRAIN LEVEL:** The striated ciliary muscles have two control centers in the cerebrum. The trophic function of the muscles, responsible for the nutrition of the tissue, is controlled from the **cerebral medulla**; the ability to contract and relax the ciliary muscles is controlled from the **motor cortex** (part of the cerebral cortex). The striated ciliary muscle of the right eye is controlled from the left side of the cerebrum; the ciliary muscle of the left eye is controlled from the right cerebral hemisphere. Hence, there is a cross-over correlation from the brain to the organ. The smooth ciliary muscles are controlled from the **midbrain**, located at the outermost part of the brainstem.

**NOTE:** The striated ciliary muscles and **extraocular muscles** share the same brain relays.

## SMOOTH CILIARY MUSCLES

**BIOLOGICAL CONFLICT:** The **biological conflict** linked to the smooth ciliary muscles is "not being able to see what is close" (difficulties reading small print, for example, in a newspaper, on a blackboard, computer screen, or phone screen), "not being allowed to see what is close", or "not wanting to see what is close" (not wanting to see what takes place right in front of one's eyes, e.g. family violence; wanting to play outside rather than doing homework).

**CONFLICT-ACTIVE PHASE:** sustained **hypertonus** (contraction) of the **smooth ciliary muscles** causing a relaxed tension on the zonules and subsequently a curved lens, which serves the **biological purpose** to be better able to see what is close. Ongoing conflict activity results in **nearsightedness** or **myopia** (see also **cornea** and **retina**).

**NOTE:** Working with fine tools (needle work) or "staring at the screen all day" strains the focusing power of the ciliary muscles leading over time to nearsightedness – without a **DHS**.

**HEALING PHASE:** During the healing phase the muscle tension goes back to normal. The **Epileptoid Crisis** manifests as **fluttering of the lens** to which the ciliary muscles or rather the zonules are attached (compare with **pupil spasms** and **nystagmus** related to the **extraocular muscles**).

## STRIATED CILIARY MUSCLES

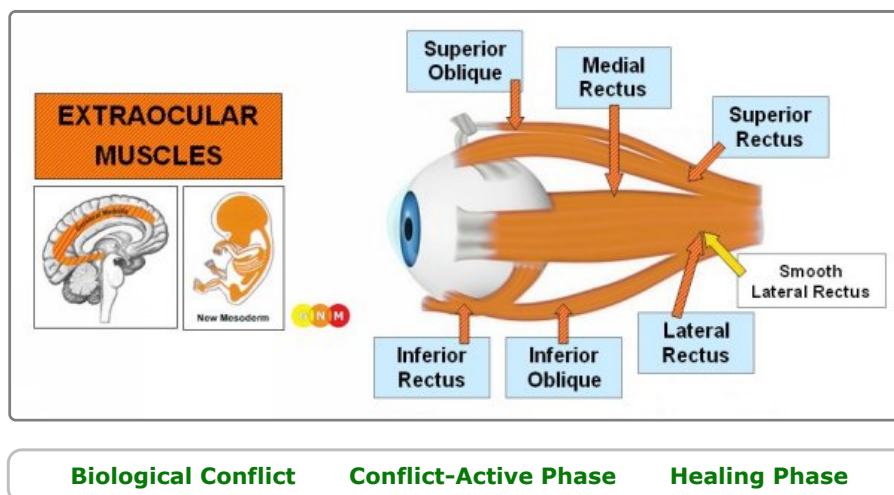
**BIOLOGICAL CONFLICT:** The **biological conflict** linked to the striated ciliary muscles is **“not being able to see what is in the distance”** (a person or object is too far away to be recognized or identified; difficulties reading a sign because it is too far away) or **“not being allowed to see what is far away”** (not being permitted to visit someone or to go on a journey) but also **“not wanting to see what is in the distance”** (a person who is leaving).

**CONFLICT-ACTIVE PHASE:** **cell loss (necrosis)** (controlled from the cerebral medulla) and, proportional to the degree of conflict activity, increasing **paralysis** (weakness) of the striated ciliary muscles (controlled from the motor cortex). This causes the zonules to tighten making the lens flat, which serves the **biological purpose** to be better able to see what is far away. Prolonged conflict activity results in **farsightedness** or **hyperopia** (see also **lens** and **retina**).

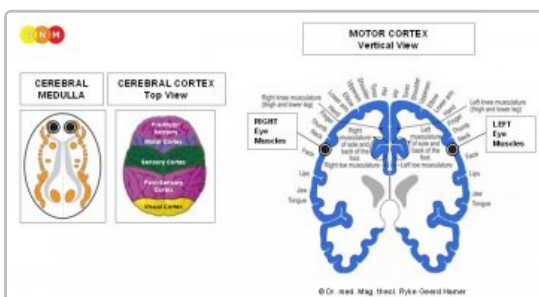
**NOTE:** The **striated muscles** belong to the group of organs that respond to the related conflict not with cell proliferation or cell loss but with functional loss (see also **Biological Special Programs** of the islet cells of the pancreas (**alpha islet cells** and **beta islet cells**), inner ear (**cochlea** and **vestibular organ**), **olfactory nerves**, **retina** and **vitreous body** of the eyes) or hyperfunction (**periosteal nerves** and **thalamus**). In case of the striated muscles, the conflict-active phase manifests as **muscle paralysis**. From a biological point of view, the paralysis is an innate fake-death reflex in response to danger.

**HEALING PHASE:** During the **healing phase** the necrosis is reconstructed and the muscle tension goes back to normal. Since the ciliary muscle is attached to the lens through the zonules, the **Epileptoid Crisis** manifests as a **fluttering of the lens** (compare with **pupil spasms** and **nystagmus** related to the **extraocular muscles**).

At the end of the healing phase the ciliary muscle will be stronger than before. This principle, namely that an organ works more efficiently after healing has been complete, applies without exception to all **cerebral medulla controlled organs**.



**DEVELOPMENT AND FUNCTION OF THE EXTRAOCULAR MUSCLES:** The extraocular muscles are six small muscles that surround the eye and control its movement. Four rectus (“straight”) muscles regulate the movement of the eyeball from left to right and up and down: the **superior rectus** moves the eye upward, the **inferior rectus** moves the eye downward, the **medial rectus** moves the eye inward (towards the nose), and the **lateral rectus** moves the eye outward (away from the nose). The two oblique muscles are primarily responsible for rotating the eyes: the **superior oblique** rotates the eye inward and downward, the **inferior oblique** rotates the eye outward and upward. The extraocular muscles are mainly made of **striated muscles** originating from the **new mesoderm**. They are controlled from the cerebral medulla and the motor cortex (compare with **smooth lateral rectus muscle**).



**BRAIN LEVEL:** The extraocular muscles have two control centers in the cerebrum. The trophic function of the muscles, responsible for the nutrition of the tissue, is controlled from the **cerebral medulla**; the ability to move the eye is controlled from the **motor cortex** (part of the cerebral cortex).

The right eye muscles are controlled from the left side of the cerebrum; the left eye muscles are controlled from the right cerebral hemisphere. Hence, there is a cross-over correlation from the brain to the organ.

**NOTE:** The extraocular muscles and **striated ciliary muscles** share the same brain relays.



**BIOLOGICAL CONFLICT:** The **biological conflict** linked to the extraocular muscles is “**not wanting to look into a certain direction**” because of something distressing “there”. Newborns, for example, suffer the conflict when they are blinded by bright fluorescent light in the delivery room. The extraocular muscles also correspond to “**not being allowed to look there**” (a student is caught cheating while he was trying to copy the exam from his neighbour) and “**not being able to look there**” (an infant is unable to look towards the mother).

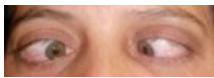**CONFLICT-ACTIVE PHASE:** **cell loss (necrosis)** of muscle tissue (controlled from the cerebral medulla) and, proportional to the degree of conflict activity, increasing **paralysis of the affected eye muscle** (controlled from the motor cortex).

**NOTE:** The **striated muscles** belong to the group of organs that respond to the related conflict not with cell proliferation or cell loss but with functional loss (see also **Biological Special Programs** of the islet cells of the pancreas (**alpha islet cells** and **beta islet cells**), inner ear (**cochlea** and **vestibular organ**), **olfactory nerves**, **retina** and **vitreous body** of the eyes) or hyperfunction (**periosteal nerves** and **thalamus**). In case of the striated muscles, the conflict-active phase manifests as **muscle paralysis**. From a biological point of view, the paralysis is an innate fake-death reflex in response to danger.

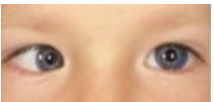
The paralysis or weakness of the eye muscle causes **strabismus**, the inability to attain binocular vision (see also strabismus caused by the damage of the oculomotor nerve due to a **pineal gland tumor**). Depending on the exact nature of the conflict, one or both eyes deviate inward, outward, upward or downward.

**NOTE:** Whether the eye muscle of the right or left eye (or both) is affected is determined by a person’s **handedness** and whether the conflict is **mother/child** or **partner**-related. A **localized conflict** affects the eye muscle that is associated with the specific **conflict** situation.

**Strabismus esotropia** (cross-eyed): one or both eyes deviate inward.

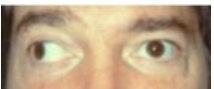

Both eyes turn inward and downward because the eye muscles that pull the eyes outwards (lateral rectus) and upwards (superior rectus) are paralyzed.



The right eye turns inward because the eye muscle that pulls the eye outward (lateral rectus) is paralyzed. If the person is **left-handed** then the conflict (“didn’t want or was not aloud to look to the right”) is associated with the **mother** or situation-related.

**Strabismus exotropia** (wall-eyed): one or both eyes deviate outward.



The right eye turns outward because the eye muscle that pulls the eye inward (medial rectus) is paralyzed. If the person is **right-handed** then the conflict (“didn’t want or was not aloud to look to the left”) is associated with a **partner** or situation-related.

**Strabismus hypertropia:** one or both eyes deviate upward.



The right eye turns upward because the eye muscle that pulls the eye downward (inferior rectus) is paralyzed. If the person is **left-handed** then the conflict (“didn’t want or was not aloud to look downward”) is associated with the **mother** or situation-related.

**Strabismus hypotropia:** one or both eyes deviate downward.



The right eye turns downward because the eye muscle that pulls the eye upward (superior rectus) is paralyzed. If the person is **right-handed** then the conflict (“didn’t want or was not aloud to look upward”) is associated with a **partner** or situation-related.

**Cyclophoria** is a type of strabismus in which the axis of one or both eyes rotates inward or outward due to the paralysis of the oblique muscles.



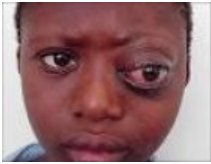If the right eye is affected and the person is **right-handed**, then the conflict (“didn’t want or was not aloud to look downward and to the right”) is associated with a **partner** or situation-related.

**HEALING PHASE:** During the **healing phase** the necrosis is reconstructed. The paralysis reaches into **PCL-A**. The **Epileptoid Crisis** presents as involuntary eye movement, called **nystagmus**. Depending on the exact nature of the conflict, the eyeball flutters up and down or side to side (compare with **fluttering of the lens** and **pupil spasms**). Recurring flutters are triggered by setting on a **track** that was established when the “don’t want to look there”-conflict took place. Uncontrollable eye movement could also occur together with a generalized seizure (grand mal) involving the entire **motor cortex**. After the **Epileptoid Crisis**, during **PCL-B**, the function of the eye muscle returns to normal.

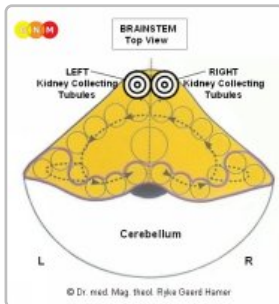
At the end of the healing phase the eye muscle will be stronger than before. This principle, namely that an organ works more efficiently after healing has been complete, applies without exception to all **cerebral medulla controlled organs**.

**Bulging eyes** (proptosis, exophthalmos) is caused by an enlargement of structures within the eye socket pushing the globe of the eyes out of the orbit – like a telescope. Continuous swelling of the **tear gland**, for example, can lead to an anterior displacement of the eye. Also, a buildup of **connective tissue**; in this case, the underlying conflict is a **self-**

**devaluation conflict.** The condition, also known as **Graves' disease or Basedow disease**, is generally associated with **hyperthyroidism**. From a GNM viewpoint, an overactive thyroid and a protrusion of the eyeball only occur together when the **thyroid conflict** is coupled with a self-devaluation conflict related to the eyes ("My eyes failed to be fast enough to catch or eliminate a morsel").



The theory of a correlation between Graves' disease and hyperthyroidism cannot explain why the eyeball protrusion affects only one eye. Based on the **principle of laterality**, a displacement of the left eye (as seen in this picture) reveals that the self-devaluation conflict is associated with the **mother**, if the boy is **right-handed**.

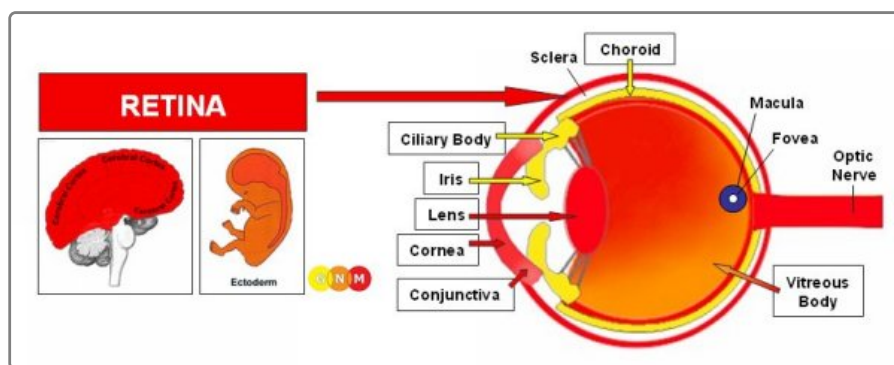


The **smooth lateral rectus** is supplied by the abducens nerve (sixth cranial nerve) that originates in the pons of the brainstem, precisely, in the control centers of the **kidney collecting tubules**.

In the event of an **abandonment and existence conflict** the lateral rectus pulls the eye(s) outward. When the conflict impacts in the right kidney tubules relay, the right eye deviates towards the right; when the left kidney tubules are affected, the left eye deviates towards the left. With two active abandonment or existence conflicts involving both kidney tubules both eyes deviate sideways. This is commonly called a **"lazy eye"**, or **amblyopia**. It should not come as a surprise that the condition often occurs in children. If the smooth part of the lateral rectus is affected, the person is able to pull the eye voluntarily into the correct position since the eye muscle is not paralysed. In this case, the person is conflict active with an **abandonment and existence conflict** rather than with a **visual "stuck"-conflict** related to the **striated lateral rectus** with paralysis in the conflict-active phase (see **strabismus exotropia**).



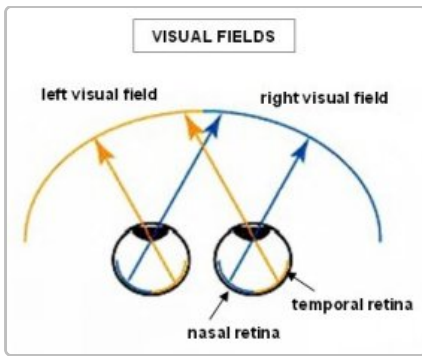
These two pictures of the French existentialist Jean-Paul Sartre show that at one time the right eye deviates outwards and another time the left eye, pointing to alternating existence conflicts.



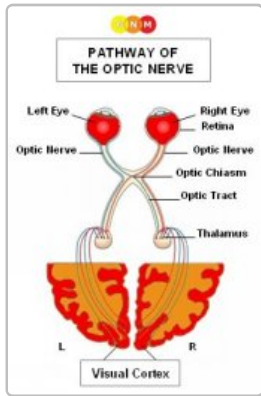
**Biological Conflict    Conflict-Active Phase    Healing Phase**

**DEVELOPMENT AND FUNCTION OF THE RETINA:** The retina is a light-sensitive layer of nerves that lines the back of the eye. It covers the underlying **choroid** and is in close contact with the **vitreous body**. The retina contains neurons such as photoreceptors (rods and cones) that receive light and colors from the **lens** and convert them into impulses that are sent via the optic nerve to the visual cortex at the back of the brain. The **macula**, located near the central portion of the retina, is responsible for central vision. Within the central macula lies the fovea, which is a small pit that permits the highest visual acuity. The retina originates from the **ectoderm** and is controlled from the visual cortex.

The **visual fields** of each eye are divided into a right and left field, called the temporal fields (close to the temporal bone) and nasal fields (close to the nose). Equally, the retina of each eye is divided into two halves: the

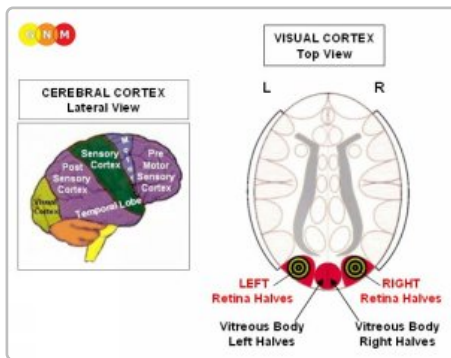


temporal retina and the nasal retina. The right halves of the retina of both eyes (orange arrows) receive images predominantly from the left visual field (90% from the left, 10% from the right) whereas the left halves of the retina (blue arrows) receive images mainly from the right visual field (90% from the right, 10% from the left). Taking into account the refraction of light by the **cornea** and the **lens**, the image projected onto the retina is actually reversed. Therefore, what is in the temporal field of vision of either eye is perceived by the nasal retina and what is in the nasal field of vision is perceived by the temporal retina (see also **vitreous body**). **NOTE:** When the eyes were still positioned on the side, the visual fields did not overlap. The joint visual fields of both eyes developed, after the eyes had moved to the front.



**Pathway of the Optic Nerve:** Visual perception, generated by photoreceptors in the retina, leaves the eyes by way of the optic nerve. The right and left branches of the optic nerve join behind the eyes, just in front of the **pituitary gland**, to form a cross-shaped structure called the **optic chiasma**. Within the optic chiasm, the nerve fibers from the nasal half of each retina cross over, but those from the temporal half do not since they are already positioned to see the reverse side of an image. After the optic chiasm, the nerves continue their path along the optic tracts. Most of the nerve fibers enter the **thalamus**. From there the nerves lead to the visual cortex at the back of the brain. The nerves of the right retina halves that receive images from the left visual field go to the right side of the visual cortex; the nerves of the left retina halves that receive images from the right visual field go to the left hemisphere. The crossing of the optic nerves at the chiasm is the requirement that the images projected onto the retina reach both sides of the visual cortex. There, the images seen by each eye are processed into a single picture, representing the image as it was originally perceived.

**NOTE:** The optic nerve emerged from the brain relays that innervated the primordial eyecup (today's **choroid**).



**BRAIN LEVEL:** The retina is controlled from the **visual cortex**. The right half of the retina of each eye is controlled from the right side of the visual cortex; the left half of the retina of each eye is controlled from the left brain hemisphere. There is no cross-over correlation from the brain to the organ.

**NOTE:** The control centers of the retina are next to the brain relays of the **vitreous body**.

**BIOLOGICAL CONFLICT:** The **biological conflict** linked to the retina relates to a **fear that cannot be shaken off** (compare with **vitreous body**). This refers to *any* fear, for example, to the fear of losing a loved one or a home, the fear of punishment, abuse, unemployment (debts, poverty), persecution (religious, ethnic, political), the fear of cancer (including medical tests and follow-up examinations), and so forth.

**CONFLICT-ACTIVE PHASE: functional loss** of retinal photoreceptor cells with the **biological purpose** to make that what evokes the fear temporarily invisible (when children are scared they cover their eyes). The loss of rod cells, responsible for vision at low light levels, results in **nyctalopia** or "night blindness" with difficulties seeing in dim light or in the dark.

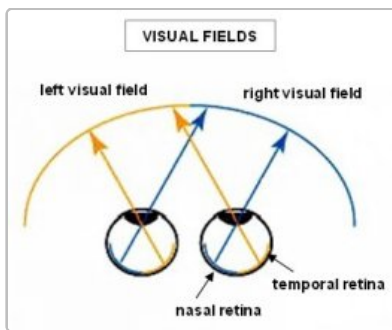
**NOTE:** The retina belongs to the group of organs that respond to the related conflict not with cell proliferation or cell loss but with functional loss (see also **Biological Special Programs** of the **vitreous body**, the inner ear (**cochlea** and **vestibular organ**), **olfactory nerves**, islet cells of the pancreas (**alpha islet cells** and **beta islet cells**), **skeletal muscles**) or hyperfunction (see (**periosteal nerves** and **thalamus**)).

Intense conflict activity causes a **diminished vision in a defined area of the visual field (scotoma)** due to the breakdown of retinal cells (compare with **scintillating scotoma**). However, with a moderate conflict the reduced vision might not be noticed since the other retina halves compensate the vision loss.

**NOTE** Whether the right or left retina halves are affected is determined by a person's **handedness** and whether the conflict is **mother/child or partner-related**.

Concerning the retina, the **principle of laterality** is reversed.

The right halves of the retina (orange arrows) look predominantly to the left



to receive images from the left visual field. Hence, for right-handed people the right retina halves relate to the mother and child(ren), for left-handers to a partner.

The left halves of the retina (blue arrows) look to the right to receive images from the right visual field. Hence, for right-handed people the left retina halves relate to a partner, for left-handers to the mother and child(ren).

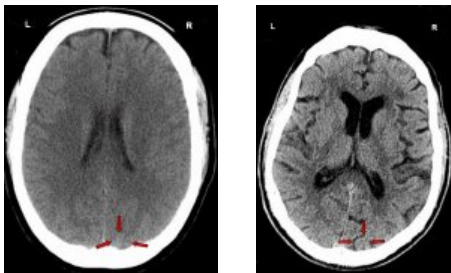
**HEALING PHASE:** During the healing phase the function of the photoreceptor cells is restored. In PCL-A an edema forms between the choroid and the affected area of the retina. During the Epileptoid Crisis the edema is expelled, which is noticeable as **flashes of light** (photopsia). The flashes could be short bursts or happen continually until the retina is repaired.



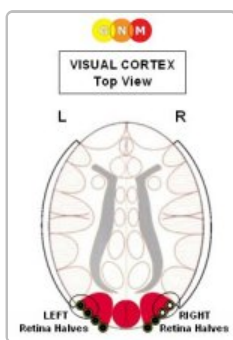
A “**scintillating scotoma**” presents as visual sparks, flickering lights, shimmering zig-zag lines, or colourful patterns in the visual field. Recurring episodes are triggered by setting on a track that was established when the original fear-conflict took place; their duration is determined by the intensity of the Epileptoid Crisis.

The visual auras often precede a migraine headache. However, not every person with migraine headache experiences them and oftentimes the auras appear without the pain of migraines. Hence, we have to consider a combination of two different Epi-Crises events.

Recurring conflict relapses lead to the buildup of scar tissue and a hardening (callosity) in the retina. If the hardening occurs laterally (on the side), the eyeball elongates causing nearsightedness or myopia (see also smooth ciliary muscle and cornea), whereas hardening in the back (dorsal) compresses the eyeball causing farsightedness or hyperopia (see also lens and striated ciliary muscle) in both eyes. At this point the condition is irreversible.



Both CT scans show a Hamer Focus (on different layers) in the right retina relay for the right retina halves of both eyes. The image on the left presents the conflict-active phase (sharp ring configuration); the image on the right the healing phase (edematous ring). For a right-handed person the fear-conflict relates to his/her mother or children; for a left-handed person to a partner (see handedness above).



**NOTE:** The right retina halves look 90% to the left and 10% to the right (the left retina halves look 90% to the right and 10% to the left) - see visual fields. If the impact of the retina-related conflict occurs in the outer portions of the right retina relay (see GNM diagram) only the right eye is affected (the same applies to the vitreous body).

A large edema between the choroid and retinal layer (usually because of water retention due to the SYNDROME) pulls the retina from its normal position. This is generally called a **retinal detachment** (strictly speaking, a misnomer since the retina does not “detach”). With no conflict relapses the condition reverses on its own. However, if the fear-conflict persists healing cannot be complete and the vision becomes drastically reduced. The panic of becoming blind often adds new fears creating a progressive condition. **CAUTION:** Stooping or physical exertion, for example when lifting something heavy, can cause a rupture of the retina!

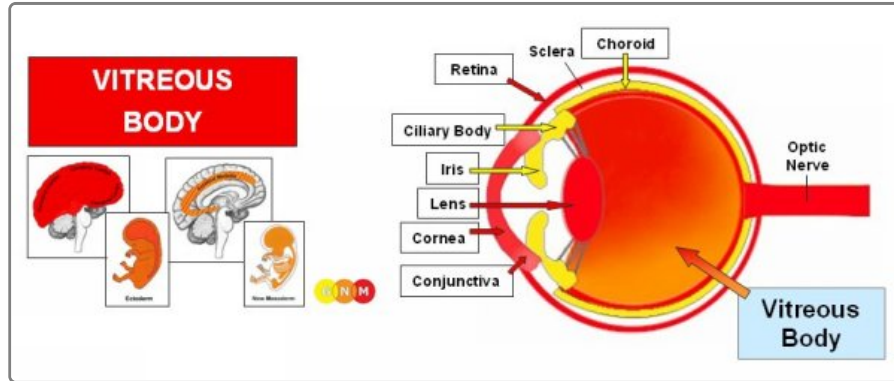
What is termed “**diabetic retinopathy**” is based on the assumption that an elevated blood sugar level damages the retina. Yet, not every diabetic develops the condition! From the GNM point of view, it is the additional resistance conflict (a resistance to the fear-provoking situation) why the two Biological Special Programs often run simultaneously (see also “diabetic peripheral neuropathy” related to the periosteum).

A **loss of central vision** develops when the healing process involves the



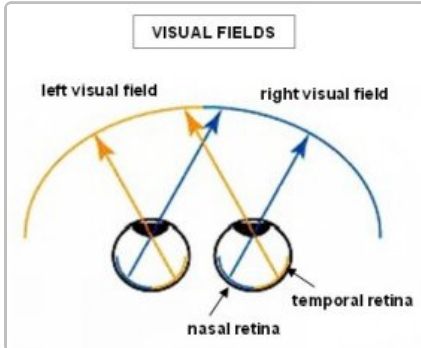
macula, a small and highly sensitive part of the retina responsible for detailed central vision (compare with loss of **peripheral vision** related to the **vitreous body**). If healing cannot be complete because of continuous **conflict relapses**, the condition can lead to blindness.

A “**dry macular degeneration**” occurs, in GNM terms, in the conflict-active phase; a “**wet macular degeneration**”, indicating the presence of an **edema** (fluid accumulation), during the healing phase.



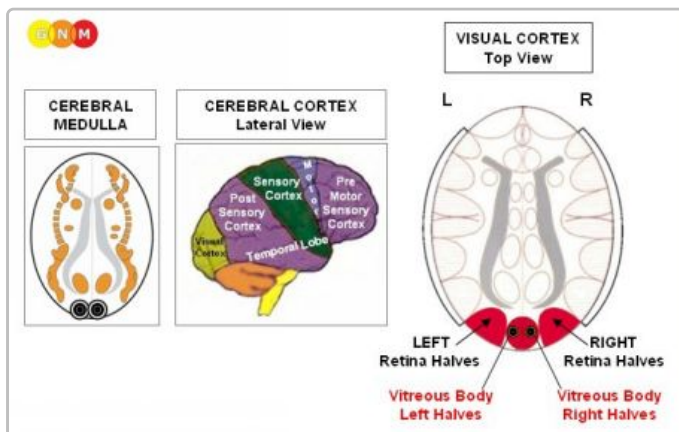
**Biological Conflict    Conflict-Active Phase    Healing Phase**

**DEVELOPMENT AND FUNCTION OF THE VITREOUS BODY:** The vitreous body occupies the space between the **lens** and the **retina** at the back of the eye. Fluid produced in the **ciliary body** fills the vitreous with a gel-like substance made up of about 99% water. The gel, composed mainly of collagen, is transparent so that light rays are able to pass through it to reach the retina. The intraocular pressure maintains the shape of the eye and prevents the walls of the eyeball from collapsing. The sclera, a sheath of **connective tissue**, supports the eyeball from the outside. The vitreous body consists of **mesodermal** parts, controlled from the cerebral medulla, and **ectodermal** parts, controlled from the visual cortex.



Like the **retina** the vitreous body is divided into two halves, a temporal vitreous (close to the temporal bone) and a nasal vitreous (close to the nose). This confirms that the vitreous body and the retina are functionally closely connected.

Analogous with the information transfer of the right and left retina halves, the images perceived from the right and left visual field go from the right and left halves of the vitreous body over the optic chiasm to the visual cortex (see **pathway of the optic nerve**).



**BRAIN LEVEL:** The control centers of the vitreous body are in the **visual cortex** (ectodermal parts) and in the **cerebral medulla** (mesodermal part). The right half of the vitreous of each eye is controlled from the right side of the cerebrum; the left halves of the vitreous of each eye are controlled from the left cerebral hemisphere. There is no cross-over correlation from the brain to the organ.

**NOTE:** The control centers of the vitreous body are next to the brain relays of the **retina**.

**BIOLOGICAL CONFLICT:** The **biological conflict** linked to the vitreous body is a **fear of a “predator”** who is “sneaking up from behind” (compare with fear-provoking conflicts related to the **retina**). Thus, the conflict is always a fear of a person, for example, the fear of an abuser, a stalker, a character assassin, a threatening ex-spouse, a relative who is after one’s inheritance, a supervisor, a teacher, a parent, a doctor, a lawyer, or an authority (government, tax

office, bailiff, police, judge) that is “breathing down one’s neck”. A fear of dogs could also evoke the conflict.

**NOTE:** Whether the right or left halves of the vitreous body are affected is determined by a person’s handedness and whether the conflict is mother/child or partner-related. As with the retina, the principle of laterality is reversed. Hence, for a right-handed person the right halves of the vitreous relate to his/her mother and child(ren), the left halves of the vitreous body to a partner; for left-handed people it is the other way around.

**CONFLICT-ACTIVE PHASE:** necrosis (controlled from the cerebral medulla) and functional loss of the vitreous body (controlled from the visual cortex), causing an interference of the transmission of light to the retina and therefore a clouding of the vitreous. This is called a “green cataract” (compare with “grey cataract” and a clouding of the lens). Considering that due to the refraction of light by the cornea and the lens the images projected onto the retina are reversed (what is perceived in the temporal field of vision is registered on the nasal vitreous), the clouding of the vitreous affects predominantly the nasal halves and therefore the peripheral vision (see visual fields). The biological purpose of the clouding is to blur the sight of the “predator” (horse-blinkers phenomenon) to be able to focus fully on the escape route.



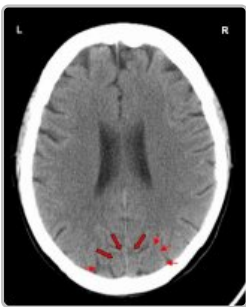
Prolonged conflict activity leads eventually to a progressive loss of peripheral vision (compare with loss of central vision related to the macula).

**NOTE:** The vitreous body belongs to the group of organs that respond to the related conflict not with cell proliferation or cell loss but with functional loss (see also Biological Special Programs of the retina, the inner ear (cochlea and vestibular organ), olfactory nerves, islet cells of the pancreas (alpha islet cells and beta islet cells), skeletal muscles) or hyperfunction (see periosteal nerves and thalamus).

**HEALING PHASE:** During the healing phase the clouding of the vitreous recedes. In PCL-A an edema (fluid accumulation) develops at the site. Frequently, the edema reaches into the opening where the optic nerve leaves the eye. During the Epileptoid Crisis the edema is pressed out. However, in order to keep the eyeball firm and prevent it from collapsing, the vitreous fluid production and intraocular pressure increase during PCL-B. This is what is called a glaucoma. The “glaucoma attack” occurs shortly after the Epi-Crisis as a result of the sudden rise of eye pressure in the vitreous. With a hanging healing due to continuous conflict relapses the condition becomes chronic. Dr. Hamer advises that laser treatment should not be performed since the vitreous body will become irreversibly damaged. Permanent elevated intraocular pressure might lead to a depression of the optic disc, termed excavation papillae (compare with papilledema caused by increased intracranial pressure; see hydrocephalus).

**NOTE:** Fluid from the vitreous body also flows into the anterior eye chamber (between the cornea and the lens) where it is absorbed into the blood. This is why elevated eye pressure never occurs in the frontal eye chamber but only in the vitreous chamber that has no blood vessels.

The scarring process (in PCL-B) is noticeable as eye floaters (mouches volantes) that appear as spots, threads, black or grey specks, strings or cobwebs that drift about with the movement of the eyes. Floaters are visible because of the shadows they cast on the retina. After the healing process has been complete, the floaters disappear.



This CT scan shows a central conflict (related to a person’s mother/child and partner) in the area of the visual cortex that controls the vitreous body (view the GNM diagram). The small arrows point to the control centers of the retina (view the GNM diagram) with a Hamer Focus in both relays. The partly edematous rings (PCL-A) indicates that the person has still relapses of fear conflicts. The combination of the Biological Special Programs of the retina and vitreous body occurs, for example, if a child lives in fear of being punished (retina) by its parents (vitreous body).